

**U.S. ARMY MEDICAL DEPARTMENT CENTER AND SCHOOL
FORT SAM HOUSTON, TEXAS 78234-6100**



SPECIAL SURGICAL PROCEDURES II

SUBCOURSE MD0928

EDITION 100

DEVELOPMENT

This subcourse is approved for resident and correspondence course instruction. It reflects the current thought of the Academy of Health Sciences and conforms to printed Department of the Army doctrine as closely as currently possible. Development and progress render such doctrine continuously subject to change.

ADMINISTRATION

For comments or questions regarding enrollment, student records, or shipments, contact the Nonresident Instruction Section at DSN 471-5877, commercial (210) 221-5877, toll-free 1-800-344-2380; fax: 210-221-4012 or DSN 471-4012, e-mail accp@amedd.army.mil, or write to:

COMMANDER
AMEDDC&S
ATTN MCCS HSN
2105 11TH STREET SUITE 4192
FORT SAM HOUSTON TX 78234-5064

Approved students whose enrollments remain in good standing may apply to the Nonresident Instruction Section for subsequent courses by telephone, letter, or e-mail.

Be sure your social security number is on all correspondence sent to the Academy of Health Sciences.

CLARIFICATION OF TRAINING LITERATURE TERMINOLOGY

When used in this publication, words such as "he," "him," "his," and "men" are intended to include both the masculine and feminine genders, unless specifically stated otherwise or when obvious in context.

TABLE OF CONTENTS

<u>Lesson</u>		<u>Paragraphs</u>
	INTRODUCTION	
1	EYE, EAR, NOSE, AND THROAT (EENT) SURGERY	
	Section I. Eye Surgery	1-1--1-17
	Section II. Ear Surgery	1-18--1-26
	Section III. Nose Surgery	1-27--1-31
	Section IV. Throat, Tongue, and Neck Surgery	1-32--1-45
	Exercises	
2	PROCEDURES IN GYNECOLOGICAL AND OBSTETRICAL SURGERY	
	Section I. Anatomy of the Female Reproductive System	2-1--2-11
	Section II. Vaginal Surgery	2-12--2-34
	Section III. Abdominal Gynecological and Obstetrical Surgery	2-35--2-44
	Exercises	
3	PROCEDURES IN GENITOURINARY SURGERY	
	Section I. Anatomy and Physiology of the Genitourinary Organs	3-1--3-8
	Section II. General Considerations in Genitourinary Surgery	3-9--3-12
	Section III. Operations on the Kidney, Ureter, and Adrenal Glands	3-13--3-21
	Section IV. Operations on the Bladder and Prostate	3-22--3-30
	Section V. Operations on the Scrotum, Penis, and Urethra	3-31--3-44
	Exercises	

**CORRESPONDENCE COURSE OF THE
U.S. ARMY MEDICAL DEPARTMENT CENTER AND SCHOOL
SUBCOURSE MD0928**

SPECIAL SURGICAL PROCEDURES II

INTRODUCTION

While each patient brings new challenges to the surgical team, there are certain problems and techniques associated with particular kinds of special surgery that can be anticipated. By preparing for these peculiarities of the various specialties, the team can circumvent a great many problems that would otherwise arise. In this subcourse, a large number of operations in various specialties are described, along with special dangers that may attend these particular procedures. The more familiar you become with these, the more effectively you will be able to do your part as a member of the operating room team.

Subcourse Components:

This subcourse consists of 3 lessons. The lessons are as follows:

- Lesson 1. Procedures in Eye, Ear, Nose, and Throat (EENT) Surgery.
- Lesson 2. Procedures in Gynecological and Obstetrical Surgery.
- Lesson 3. Procedures in Genitourinary Surgery.

Credit Awarded:

To receive credit hours, you must be officially enrolled and complete an examination furnished by the Nonresident Instruction Section at Fort Sam Houston, Texas. Upon successful completion of the examination for this subcourse, you will be awarded 8 credit hours.

You can enroll by going to the web site <http://atrrs.army.mil> and enrolling under "Self Development" (School Code 555).

A listing of correspondence courses and subcourses available through the Nonresident Instruction Section is found in Chapter 4 of DA Pamphlet 350-59, Army Correspondence Course Program Catalog. The DA PAM is available at the following website: <http://www.usapa.army.mil/pdffiles/p350-59.pdf>.

LESSON ASSIGNMENT

LESSON 1

Eye, Ear, Nose, and Throat (EENT) Surgery.

TEXT ASSIGNMENT

Paragraphs 1-1 through 1-45.

LESSON OBJECTIVES

After completing this lesson, you should be able to:

- 1-1. Identify terms and their definitions that are related to EENT surgery.
- 1-2. Identify preparation procedures of the operating room and of the patient for EENT surgery.
- 1-3. Identify special safety precautions related to EENT surgery.
- 1-4. Identify specific EENT surgical instruments.
- 1-5. Identify specific surgical procedures used for EENT surgery.
- 1-6. Identify procedures for tongue and neck surgery.

SUGGESTION

After completing the assignment, complete the exercises at the end of this lesson. These exercises will help you to achieve the lesson objectives.

LESSON 1

EYE, EAR, NOSE, AND THROAT (EENT) SURGERY

Section I. EYE SURGERY

1-1. INTRODUCTION

a. **General.** The anatomy, physiology, and the location of the eye make surgery upon the eye a highly specialized field of surgery. Therefore, procedures done by the specialist when assisting with eye surgery differ from procedures used for other surgical specialties. However, the principles of asepsis and safe, skillful care apply as in all other surgery. The ensuing text presents a discussion of the necessary considerations that are applicable in the majority of cases in this specialty.

b. **Special Care of Instruments.** The specialist is to use exacting care when working with instruments for eye, ear, nose, and throat surgery because most of these instruments are delicate. Sharp surfaces of these instruments must be preserved to ensure the success of the operative procedure. The specialist is to follow local policy in the care and handling of these instruments.

c. **Anatomy and Physiology of the Eye.** The eye is also referred to as the eyeball or globe. In the adult, it is slightly less than one inch in its longest diameter. See figure 1-1 for parts of the eye.

(1) The lids and anterior surface of the eye, except for the center, are covered by the conjunctiva.

(2) The cornea forms the anterior center of the eye and transmits and refracts light. Behind it, the anterior chamber contains the iris (which gives eye color and forms the pupil) and the aqueous humor.

(3) The lens focuses light on the retina allowing for near and far vision.

(4) The posterior chamber contains the jelly-like vitreous humor, which helps give rigidity to the eye.

(5) The retina receives light and converts it to impulses to the brain via the optic nerve.

(6) The main body of the eye is made of three layers called tunics. The external tunic includes the sclera (the white part of the eye) and clear cornea. The middle tunic includes the choroid, the ciliary body, and the iris. The iris is the colored part that changes the aperture size over the eye lens. The internal tunic is sometimes called the nervous covering, but is usually referred to as the retina. The retina is a thin network of nerve cells and fibers that receives the images of objects the eye is seeing.

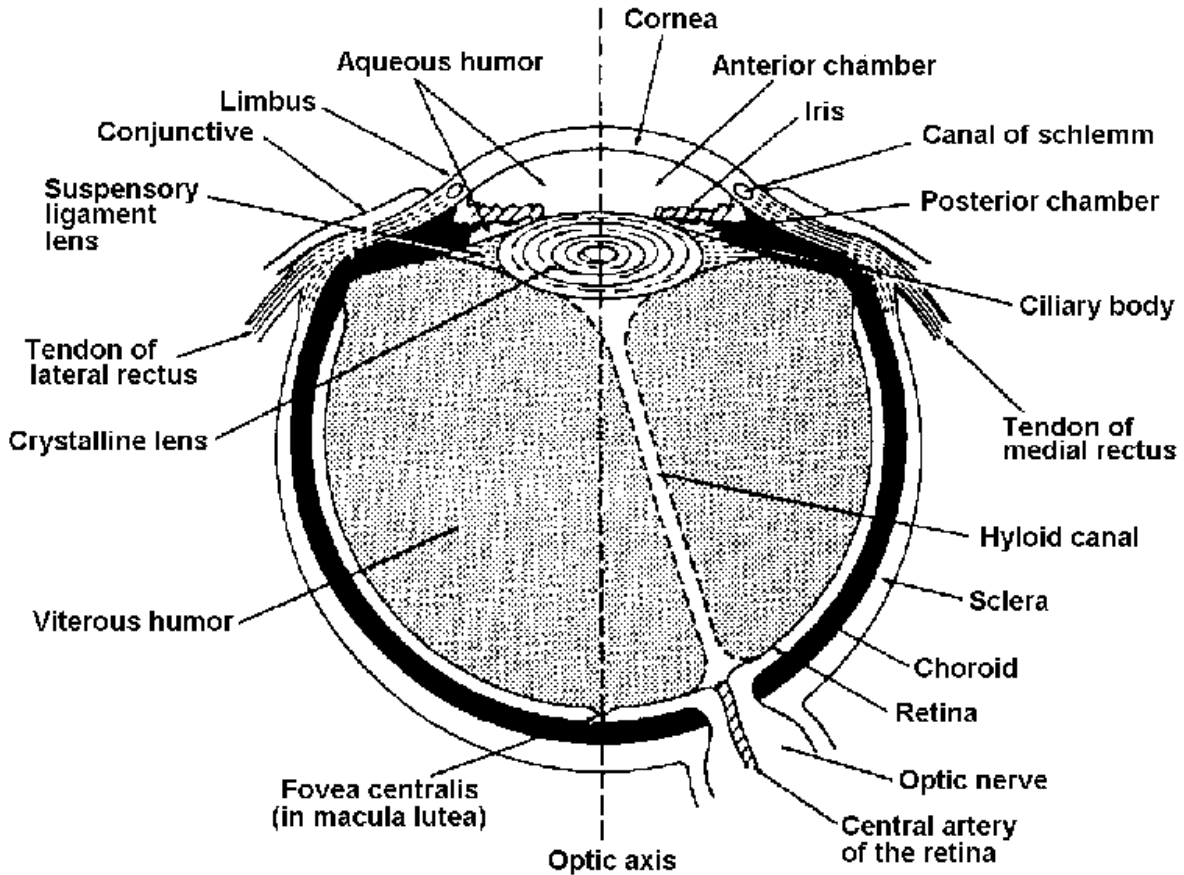


Figure 1-1. Parts of the eye.

1-2. SPECIAL PREPARATION OF THE OPERATING ROOM

a. **Instruments.** All instruments used for eye surgery are made for this purpose, and are unlike those for surgical procedures in other areas of the body. Preferences for instruments vary so widely among eye surgeons that it may be necessary to list all instruments used for each operation by each different surgeon. Therefore, the surgeon's card must be carefully checked when selecting instruments for an eye operation.

b. **Sponges.** Gauze sponges are considered much too rough for use on an eyeball. Instead, dampened cotton applicators are used. Special cellulose sponges, specifically designed and prepackaged sterile by manufacturers for eye surgery, are also available.

c. **Magnifying Glasses.** The surgeon may wish to use special magnifying glasses during the procedure; therefore, these must be cleansed and ready for use.

d. **Lighting.** Illumination for eye surgery may be furnished by a number of methods.

(1) One method is the use of the standard overhead light. The circulator may be responsible for adjusting the light during surgery. If this need occurs, he should pay particular attention to not contaminating the sterile field and scrubbed personnel.

(2) A second source is the use of an electric head lamp. This lamp is strapped to the surgeon's head and is used in the same manner as a coal miner's helmet. The surgeon may redirect the light during surgery.

(3) The third method is the use of the operating microscope. This is a device used to magnify the site of surgery and enable the surgeon to do very delicate work with excellent illumination. This device is draped with sterile material before the procedure is started, and the surgeon may make any adjustments. The microscope is being used more and more for eye and other delicate surgery.

e. **Medications.** As many as 5 or 6 solutions may be kept within the sterile field for use during eye procedures; examples of these are saline (for dampening the eyeball), local anesthetic agents, and epinephrine. If these are not prepackaged and sterilized in individually labeled doses, the specialist should label medicine glasses to show the name and the strength of each solution. During preparation for an operation, the circulator should pour the solutions needed into the medicine glasses, making sure that the solution he is pouring matches the label on the glass. Great care should be taken to assure that ophthalmic solutions of the desired drugs are used.

f. **Sterile Setup.** If both of the patient's eyes are to be operated on for correction of defects requiring muscle surgery or other extraocular procedures, only one Mayo table needs to be up. However, if intraocular surgery is to be performed on both eyes, the specialist sets up two tables--one for each eye. When the procedure on the first eye is completed, the surgeon and specialist change only their gloves in preparation for the second eye.

NOTE: A large percentage of intraocular surgery does not require double setups. Advancement in techniques and equipment makes the practice ineffective and costly.

1-3. PREPARATION OF THE PATIENT

a. **Preoperative Prep.** For a successful operation, the physical, spiritual, and emotional needs of the person must be considered. Each member of the staff should endeavor to meet the needs of each patient and help him to cope with his specific problems.

(1) Emotional factors.

(a) The loss of vision or any interference with the use of the eyes, even temporarily, has a severe emotional effect on any person. It means loss of mobility and ability to take care of or protect oneself. This tends frequently to make the patient nervous and sometimes depressed. The patient is often awake during the entire operation. All operating staff members should allay the fears of each patient. The emotional state of the patient is an important factor in a successful recovery.

(b) A quiet environment and a calm, kindly, understanding voice create confidence in the patient. The patient's comfort is further enhanced by pleasant surroundings and freedom from noise and confusion. When a patient is sedated, he is often unable to speak coherently, but is usually conscious of noises, which become exaggerated in his mind.

(2) Drugs which may be given.

(a) To allay anxiety and reduce general muscle tone, the patient is usually given a barbiturate-narcotic drug on call to surgery, as well as any ophthalmic drugs that may be prescribed. This is often followed by topical anesthetic drops upon arrival at surgery (see figure 1-2).

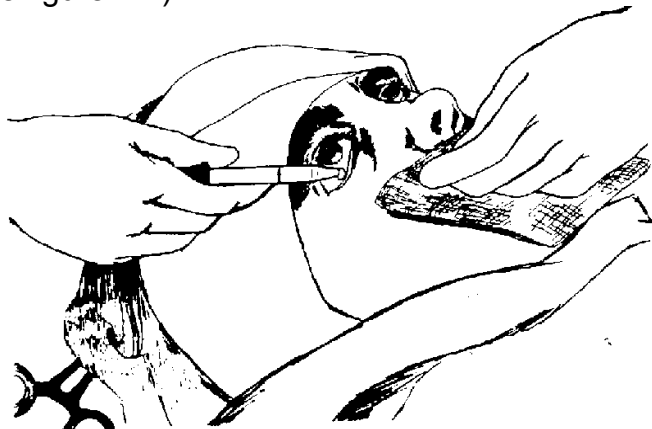


Figure 1-2. Instillation of eye medication.

NOTE: Observe the position of the dropper and the capillary attraction.

(b) Mydriatic drops are used to dilate the pupil with the patient retaining the ability to focus his eye. This is usually 10 percent phenylephrine (Neo-Synephrine[®]).

(c) Cycloplegic drugs dilate the pupil and prevent focusing of the eye. Commonly used cycloplegics are 1 percent tropicamide (Mydriacyl), 1 percent atropine, and 1 percent cyclopentolate (Cyclogyl[®]). Atropine has a long-lasting effect.

(d) Miotic drugs cause the pupil of the eye to contract. Commonly used miotics are 1 percent to 4 percent pilocarpine and 0.012 percent to 0.25 percent phospholine iodides[®]. Miotics improve the ease with which the aqueous fluid escapes from the eye independent of their action on the pupil, thereby resulting in decrease of intraocular pressure. Miotics are used in the treatment of glaucoma. These drugs increase contraction of the sphincter of the iris, thus causing it to become smaller. Phospholine iodide[®] is usually discontinued before intraocular surgery is performed.

(e) A great number of corticosteroid preparations exist. They are used to prevent the normal inflammatory response to noxious stimuli. Corticosteroids reduce the resistance of the eye to invasion by pathogens; therefore, they are not used in the presence of infection.

(f) Topical antibiotics are often used prophylactically to prevent infection. Antibiotic instillation may be given prior to intraocular surgery to help prevent wound infection. Zinc sulfate, 0.25 percent, is used to reduce redness and swelling and to soothe tissue. It may be ordered in combination with a 0.125 percent preparation of phenylephrine. Zinc also is a necessary cofactor in wound healing. Lubricating drops or ointments such as Methylcellulose, 0.5 percent, are often used to protect the cornea.

(g) Hyperosmotic agents increase the osmolarity of the serum and, by the effect of the induced osmotic pressure gradient, shrink the vitreous body and reduce the intraocular pressure. These drugs are used routinely in the preoperative medication of patients about to undergo ophthalmic surgery, as well as therapeutically in cases of uncontrolled glaucoma. These drugs, given either orally or by injection, induce diuresis, so nursing personnel have urinals and sterile catheters on hand.

b. Admission into the Operating Room. When the patient is admitted to the operating room, the nursing team should:

(1) Make positive identification of the patient by name, dealing with him in a gentle, kind, and professional manner.

(2) Check the patient's name on his wristlet band with the name on the chart.

(3) Prepare the operating table, making sure all the necessary attachments for the table are in proper readiness.

c. Preparation of the Patient's Face.

(1) Preparation of the patient is done under aseptic conditions. Topical anesthetic drops are administered first if the patient is to be given a local anesthetic. A sterile preparation tray containing sterile normal saline solution, irrigation bulbs, basins, cotton, sponges, towels, and antibacterial skin disinfectant should be near the operating table.

(2) Neither the clipping of eyelashes nor shaving of eyebrows is done routinely. When eyelashes are clipped, this is done prior to the skin preparation. A thin film of petrolatum is smoothed over the cutting surfaces of the curved eyelash scissors so that free lashes will adhere to the blades. This prevents the free eyelashes from falling into the eyes or onto the face.

(3) The preparation includes cleansing the eyelids of both eyes, lid margins, lashes, eyebrows, and surrounding skin with an antibacterial soap or disinfectant. To prevent the agent from entering the patient's ears, they may be temporarily plugged, using cotton pledgets. Care is taken to keep the agent out of the eyes. The preparation area is washed with warm sterile water, using soft-texture gauze or cotton sponges. The operative area is painted with an aqueous nonirritating skin antiseptic.

(4) When toxic chemicals or small particles of foreign matter must be removed, the eyes may be irrigated with tepid sterile normal saline solution. The conjunctival sac is thoroughly flushed, using an irrigating bulb or an Asepto syringe.

d. **Draping the Patient.** For general eye surgery, the basic draping procedure is as follows:

(1) A large, folded sheet is needed to cover the patient and operating table.

(2) The head is draped with a double-thickness half sheet and two towels or appropriate disposable drapes.

(3) A fenestrated eye sheet, 14 inches square, with a center opening of 2 1/2 x 3 inches, is placed over the operative site. More recently, disposable plastic drapes have been used.

e. **Anesthesia.** Local anesthesia is frequently preferred and indicated for eye surgery, especially in elderly individuals and in those with circulatory and other systematic diseases. A sedative is given the night before surgery and again two hours prior to surgery.

(1) Anesthesia setup. The operating room staff assembles the sterile local anesthesia setup as ordered by the surgeon before the patient enters the operating room and checks the bottles of drugs to make sure they are the correct medications and of the proper strength.

(2) Needles and syringes.

(a) Subcutaneous injection and infiltration. Two Luer-Lok 2-ml syringes and two 25-gauge needles, 1/2-inch length may be used.

(b) Subconjunctival injection. Two Luer-Lok 2-ml syringes and two 26- or 27-gauge needles, 1- or 1 1/2-inch length.

(c) Retrobulbar injection. Two Luer-Lok 2-or 5-ml syringes or one 10-ml syringe and two 24-gauge needles, 1-or 1 1/2-inch length.

(3) Frequently-used drugs.

(a) Tetracaine hydrochloride (Pontocaine hydrochloride[®]) in a 2 percent solution may be instilled into the eye before an operation. For local anesthesia in adults, 2 percent lidocaine (Xylocaine[®]) with epinephrine hydrochloride in a 1:150,000 or 1:200,000 dilution is frequently used.

(b) Hyaluronidase (Wydase[®], Alidase) is commonly mixed with the anesthetic solution (75u/10ml). The enzyme increases the diffusion of the anesthetic through the tissue, thereby improving the effectiveness of the anesthetic nerve block. For cataract surgery, an effective retrobulbar injection reduces intraocular pressure by preventing positive muscle contraction, thus becoming a surgical safeguard against vitreous loss. Hyaluronidase is nontoxic and is effective over a wide range of concentrations.

(c) In cataract surgery, alpha chymotrypsin in a 1:5,000 or 1:10,000 solution may be used to dissolve the zonular fibers that suspend the cataract within the eye. To produce eye muscle paralysis in intraocular surgery, tubocurarine chloride or succinylcholine chloride may be administered intravenously by the anesthesiologist.

(d) Epinephrine in a 1:1,000 solution may be applied topically to mucous membranes to decrease bleeding. Epinephrine in a 1:500,000 to 1:200,000 solution may be combined with injectable anesthetics to prolong the duration of anesthesia. Epinephrine in a 1:1,000 solution is not used in local anesthetics because if it were used in such concentrations, the patient could succumb to cardiac arrhythmia.

(4) Methods used for administration of local anesthetics. The three methods of administration are instillation of eye drops, infiltration, and block or regional anesthesia.

(a) Instillation of eye drops. With the patient's face, tilted upward, the first drop is placed in the lower cul-de-sac, and the following drops (number depends on the type of operation to be performed) may be placed from above, with the patient looking downward and the upper lid raised. However, the natural blinking of the lids distributes the drug evenly on the eye surface, regardless of where the drop is placed. When a toxic drug is instilled, the inner corner of the eyelids should be dried of excessive fluid with a tissue or clean cotton ball after the instillation of each drop, thereby minimizing systemic absorption of the drug. The tip of the applicator must not touch the patient's skin or any part of the eye.

(b) Infiltration method. The surgeon injects the anesthetic solution beneath the skin, beneath the conjunctiva, or into Tenon's capsule, depending on the

type of surgery. Retrobulbar injection is usually performed 10 to 15 minutes before surgery to produce a temporary paralysis of the extraocular muscles.

(c) Block or regional anesthesia. The solution is injected into the base of the eyelids at the level of the orbital margins or behind the eyeball to block the ciliary ganglion and nerves. For eyelid repairs, the solution is introduced through the lower lid. For operations on the lacrimal apparatus, the anesthetic is injected at the level of the anterior ethmoidal foramen in order to anesthetize the internal and external nasal nerves. In the Van Lint block method, procaine solution is injected into the orbicular muscle and reaches the ends of the facial nerve.

(5) General anesthesia. A general anesthetic, with or without intravenous injection of thiopental sodium (Pentothal Sodium[®]) is used when a patient is unable to cooperate because of youth, dementia, or nervousness, or because the solutions of 20 percent mannitol (Osmitrol[®]) or 5 percent glucose in water are given intravenously during surgery. A sedative is given the night before surgery, and a drying agent (atropine or scopolamine) and an analgesic are given 1 to 1 1/2 hours prior to surgery. The patient must not eat or drink anything for 6 hours prior to induction.

1-4. CONSIDERATIONS AT THE COMPLETION OF SURGERY

a. At the completion of the operation, the surgical area is cleansed, using saline sponges.

b. Antibiotic ointment may be thinly spread over the skin and eyelashes to prevent adhesion of the bandage. This is frequently done after plastic procedures on the lids or lacrimal duct.

c. Dressings are applied to prevent palpebral movements, protect the operative wound from dust and external contaminants, and absorb any blood and tears that are produced.

d. The initial dressing usually consists of a piece of fine cotton. An eye pad that is commercially prepared and sterilized is applied over the cotton splint. The eye dressing may be held in place by means of paper tape.

e. After intraocular operations, when external pressure on the eyes might be very harmful, the initial dressing is covered with a protector such as a wire gauze cap, perforated aluminum plate, convex perforated metal cup, convex flexible celluloid plate, or some other kind of shield.

f. A pressure bandage may be used in some cases when a compression effect is desired. The gauze roller bandage is applied over the initial dressing, encircling the head.

g. The instruments are carefully cleaned and sterilized.

1-5. SPECIAL SAFETY PRECAUTIONS

The precautions set forth for eye surgery should be scrupulously observed by the specialist as well as all other members of the operating room team, because errors or carelessness could cost the patient his sight.

a. **Eye Medications.** There must be absolutely no error in the administration of any solutions. In addition, all solutions must be sterile and fresh.

b. **Room to Breathe.** There must be sufficient ventilation for the patient beneath the drapes.

c. **Quiet, Calm Room.**

(1) To perform eye surgery satisfactorily, the surgeon must have a skilled and steady hand, and he must be able to concentrate on the operation. To maintain the needed quiet, calm atmosphere, all team members should keep conversation low and at a minimum. The movements of all team members should be executed smoothly and gently. This is especially important for persons working near the operative area. In addition, a sign should be placed outside the door to warn others that eye surgery is in progress and to keep traffic with its noise and confusion out of the area.

(2) When the patient has been given local anesthesia, it is necessary that he lie still without moving his head. Even though he is awake, his unaffected eye may be left uncovered; he may move if there is a loud noise or hurried activity near him.

(3) Eye instruments should be cleaned after each use during the operation with a nonfibrous sponge. After the operation, the instruments should be cleaned and dried thoroughly before storage. Microsurgical instruments should undergo ultrasonic cleaning with distilled water and appropriate cleansing agent. They should be individually hand held or immersed in ultrasonic cleaner as long as they are not touching each other. The instruments should be rinsed with distilled water and thoroughly dried.

NOTE: A regular preventive maintenance program should be established for sharpening, realigning, and adjusting the precision eye instruments.

d. **Instruments and Their Care.** Eye instruments are delicate and are assembled and stored in specialized instruments cases. They are easily bent, broken, or dulled. These instruments are also expensive and they must be handled with these characteristics in mind.

(1) Eye instruments are never to be stacked--before, during, or after a surgical procedure. The specialist should carefully arrange the instruments on the table so that no instrument is touching another, and they must not be stacked or thrown down carelessly at any time.

(2) Eye knives require even more scrupulous care. The blades must be protected by suspension at all times when they are not actually touching the patient's eyes. In some instances, they are tested before use with a thin kidskin stretched over a drum. The knives must be capable of cutting without any pressure being applied to the knife.

(3) A basic eye surgery instrument set with the addition of other instruments, supplies, and suture materials as preferred by the surgeon, will usually suffice for all of the more detailed minor surgery performed on the eye. Examples of such minor surgery are tarsorrhaphy, repairs of eyelid lacerations, and repair of conjunctival lacerations. The basic eye instrument set will include:

- (a) Self-retaining eye speculum.
- (b) Lid retractor.
- (c) Muscle hooks.
- (d) Knife handle.
- (e) Scissors (tenotomy, stitch, corneal, and iris).
- (f) Forceps (suturing fine and heavy, iris, fixation, tying).
- (g) Caliper.
- (h) Needle holders (micro and heavy).
- (i) Irrigating cannula (19- and 27-gauge).
- (j) Iris spatula.

1-6. HANDLING OF SPECIMENS

Whenever tissue removed during eye surgery is to be either examined for pathology or processed for storage in a "bank," the specimen is processed as described in Subcourse MD0927.

1-7. SUTURING TYPES USUALLY USED

Preferences vary among eye surgeons both as to the size and kind of sutures used and the type of stitch used. Therefore, the specialist should carefully check the surgeon's preference card for the procedure before preparing any sutures. In general, the sutures used for eye surgery are much smaller than those used for operations on other parts of the body. Silk, size 6-0, is frequently used, as is plain catgut in small sizes. In addition, double-arm sutures (a suture with a needle swaged on both ends)

are used for many operations. The specialist prepares this suture as described for swaged-on sutures, taking care not to exert pull on either of the needles. He must also avoid pricking his gloves with the needles. Both of the swaged-on needles are clamped into needle holders before the suture is handled. Either interrupted or continuous stitches may be taken, depending upon the preference of the surgeon.

1-8. OPERATIONS ON THE EYES

a. **Introduction.** In the following text, some examples of surgical procedures on the eyes are defined in order to acquaint the specialist with these operations. When the specialist is assigned to scrub or circulate for an eye operation, he is to perform duties as indicated in paragraphs 1-3 through 1-7, using whatever modifications may be prescribed locally.

b. **Extraocular (Outside the Eye) Procedures.** The operations discussed in paragraphs 1-9 through 1-11 are those done outside the eye. Anesthesia used maybe either general or local depending upon the needs of the situation.

c. **Intraocular (Within the Eye) Procedures.** Operations performed within the eye are discussed in paragraphs 1-12 through 1-17. Anesthesia of choice is usually--though not always--local.

1-9. PROCEDURES ON EYELIDS

a. **Plastic Repair of Eyelid.** Various reconstructive techniques may be employed by the surgeon in repairing the eyelid following lacerations or burns. Plastic repair may also be indicated as treatment for acquired malfunctions of the eyelid. Such malfunctions sometimes result from scars that form after the healing of injuries or burns of the lids. These malformations may be classified as follows:

(1) Ectropion. This is the rolling outward of the eyelid margin so that a portion of the conjunctiva is exposed. It is usually accompanied by epiphora (tears running down the cheek). This condition may be caused by injury or it may occur spontaneously in elderly persons with no history of injury.

(2) Entropion. This is the rolling inward of the lid margin so that it presses against the cornea and the eyelashes are in contact with the eyeball.

b. **Tarsorrhaphy.** This is the surgical closure of the lids by a plastic operation. It is indicated when the lids cannot close sufficiently to cover the cornea during sleep (exposure of the cornea results in the drying of its surface and produces corneal ulcer).

c. **Excision of Chalazion.** A chalazion is a small benign tumor of the eyelid. The removal of a chalazion is indicated when the chalazion fails to disappear without surgical intervention in the course of several weeks. (Approximately 70 percent of chalazia require excision.) In addition, excision is indicated if the chalazion progressively enlarges.

(1) The surgeon may excise the chalazion through either the conjunctival surface or the skin of the lid (see figure 1-3). The route of excision depends upon the surface upon which the chalazion is located. Very fine silk suture on a swaged-on needle is used if excision is through the skin surface. No suture is required if excision is through the conjunctival surface.

(2) A chalazion set is used with other instruments, supplies, and sutures according to the surgeon's preference.

d. **Excision of Pterygium (Benign Growth of Conjunctival Tissue Over the Cornea).** Removal of a pterygium is indicated when the pterygium is progressive and is invading the cornea.

e. **Hordeolum (Sty).** A sty is an infection of one or more glands of the skin of the eyelid. A painful lump occurs in the skin and the abscess, which can form may break through the surface and drain pus. Although the common treatment is application of hot compresses, pointing may necessitate opening and draining.

f. **Ptosis.** Ptosis is a drooping of the upper eyelid. It can be caused by neurological disorder, ocular conditions such as microphthalmus (abnormal smallness of the eyes), and local injury such as traumatic rupture of the levator muscle as well as other malfunctions. Lid surgery may be indicated if other treatments cannot remove the causes.

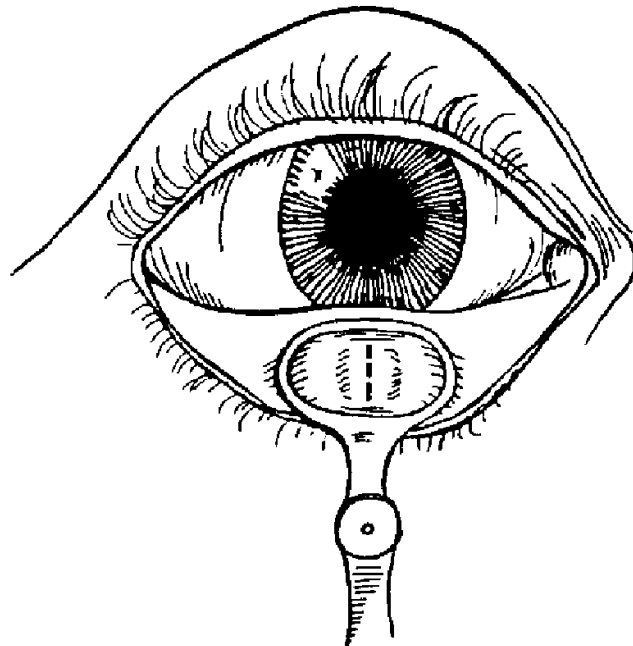


Figure 1-3. Preparation of eyelid for Chalazion removal. The incision on the inner lid surface is to avoid scarring.

1-10. PROCEDURES ON LACRIMAL APPARATUS (TEAR-DUCT SYSTEM)

a. **Dacryocystectomy.** A dacryocyst is a lacrimal (tear) sac. Therefore, dacryocystectomy is excision of the wall of the lacrimal sac. It is indicated as treatment for acute dacryocystitis. A lump may appear under the skin at the inner corner of the eye as the tear sac fills with pus. If the pus cannot be discharged from the sac by pressing on it, the ducts may be blocked and surgical incision and drainage of the sac is required to relieve the condition.

b. **Dacryocystorhinostomy.** This is the construction of an opening from the tear sac into the nasal cavity. The surgery may be done as treatment for chronic dacryocystitis, trauma to the nasolacrimal duct, or congenital malformation of the duct. In children, early probing of the nasolacrimal duct (before age of 1) may prevent the need for a dacryocystorhinostomy later.

1-11. PROCEDURES ON EXTRAOCULAR MUSCLES

a. **General.** Operations on muscles outside the eyeball are done for correction of strabismus. Strabismus is a term describing muscle imbalance between two eyes. An eye deviating outward or away from its fellow eye is a condition termed exotropia. If the eye deviates inward, it is termed esotropia.

b. Objective of Surgery.

(1) To secure binocular single vision by performing accurate binocular alignment.

(2) To achieve alignment that allows the best possible cosmetic effect and enables maintenance of the effect for as long as possible.

c. **Kinds of Operations.** Strabismus may be treated surgically by procedures done either to strengthen weak muscles (refer to paragraphs 1-11d, e, and f below) or to weaken overactive muscles (refer to paragraphs g and h below).

d. **Tucking.** A tuck is sutured in the muscle, thus shortening it and increasing its effective strength.

e. **Advancement.** The muscle is freed at its attachment point, and it is reattached closer to the cornea, thus increasing its leverage.

f. **Resection (Shortening).** Part of the tendon of an extraocular muscle is excised. The muscle is reattached to the sclera at the original point of insertion.

g. **Tenotomy.** This is transection of the muscle sheath and tendon.

h. **Recession (Lengthening).** The muscle is detached from the eyeball and is sutured to the sclera posterior to the original insertion.

1-12. PROCEDURES ON THE EYEBALL

a. **Enucleation.** This is excision of the eyeball and its muscles, with or without introduction of an implant (device made of glass or plastic used to prevent unsightly appearance of the eye and to form, a base for a prosthesis). Enucleation is sometimes indicated as treatment following penetrating or crushing wounds of the eyeball, and upon diagnosis of certain other conditions--especially the threat of sympathetic ophthalmia. (Sympathetic ophthalmia is bilateral inflammation of the entire uveal tract.) The condition is nearly always secondary to a perforating wound of the eye. Sympathetic ophthalmia nearly always progresses to blindness unless the injured eye ("exciting eye") is removed before the disease is well underway in the other eye ("sympathizing eye"). The anesthesia of choice for this operation is general anesthesia.

b. **Evisceration.** In contrast to enucleation, evisceration is excision of the cornea and removal of all contents of the globe, leaving the scleral shell and muscles intact. The procedure is indicated following injury when a virulent organism invades the eye. Evisceration provides less danger of the transmission of infection to the brain than does enucleation. General anesthesia is usually used for this procedure.

c. **Exenteration of Orbit.** This is the removal of the entire contents of the orbit (eye, tendons, muscles, fatty and fibrous tissue). The operation is indicated as treatment for malignant tumor. General anesthesia is usually given for this procedure.

1-13. PROCEDURES FOR REPAIR OF DETACHED RETINA

a. **General.** A retinal detachment is a separation of the portion of the retina that contains the rods and cones from the portion of the retina called the pigment epithelium. As a result, the rods and cones lose nutrition and cease to function. Thus, the visual defect will vary with the extent and location of the detachment.

(1) There are many causes for a retinal detachment. These include trauma, high myopia (causing a thin retina), degeneration, diabetes, infections, and tumors. The danger of a small retinal detachment is that eventually the entire retina will separate and the eye will lose all vision.

(2) Blood or fluid may be present as a result of direct or indirect trauma, severe inflammation, or certain diseases.

b. Operative Procedures.

(1) If the retina is detached as a result of tumor, enucleation may be the operation indicated.

(2) Retinal detachment due to the presence of blood or fluid offers a choice of several operative procedures to the surgeon. All operations are based on the principle of sealing off the area in which the tear has been located, of draining off

sub-retinal fluid, and of creating a watertight adhesion between the choroid and the retina. A frequently used operation involves the use of electrocautery. The surgery may be performed using general or local anesthesia.

1-14. PROCEDURES FOR REMOVAL OF INTRAOCULAR FOREIGN BODIES

a. **General.** The presence of an intraocular foreign body usually represents a serious ocular problem. Disturbance of the function of the eye results from several sources, including the destruction of or damage to the tissues caused by the entrance of a missile; infection introduced by the missile; and destruction of or damage to the delicate intraocular tissues caused by reactions to the intraocular intruder, such as siderosis caused by iron or inflammation caused by wood particles.

(1) Before surgery is undertaken, the size and location of the foreign body must be determined. This is done by special X-ray procedures of the skull with special bone-free X-ray using dental film and other techniques.

(2) In addition, metal-locating instruments and ultrasonic probes are employed to locate the foreign bodies.

b. **Operative Procedures.** The operation performed depends upon the size, location, and magnetic property of the embedded object. Local anesthesia is used because the cooperation of the patient is required.

(1) The magnet tip may be directed to the eye and the foreign body removed without incision into the eye if the size and location of the object makes this procedure feasible.

(2) If the size, shape (jagged edges), or the location of the foreign body is such that passage of the object would endanger structures vital to vision, the sclera is incised and the magnet tip is advanced into the vitreous, humor for removal of the object.

(3) A nonmagnetic foreign body is removed by incision and extraction, but it must be seen to be removed.

1-15. PROCEDURES IN THE TREATMENT OF CATARACT

a. **General.** Cataract is a clouding or an opacity of the crystalline lens, its capsule, or of both. A cataract may result from local or systemic disease, from eye injury, or the cataract may be congenital. Cataracts seen in the elderly are referred to as primary or senile cataracts. Medical treatment of cataracts is not available. Only surgical removal of the lens is of any significant assistance and this is indicated when the patient's vision is sufficiently depressed.

b. Operative Procedures.

(1) Discussion, or needling of lens. The capsule is incised and the lens substance is broken up. The aqueous humor exerts a solvent action on the exposed lens tissue, thus a clear opening for the passage of light is obtained. The principal use for needling is in cases of cataract due to trauma and in cataract surgery performed on children.

(2) Iridectomy. A sector of the iris is removed as a preliminary step in extraction of the cataract (lens extraction).

(3) Lens extraction, intracapsular. The entire lens within the capsule is removed intact through a corneoscleral incision (see figure 1-4).

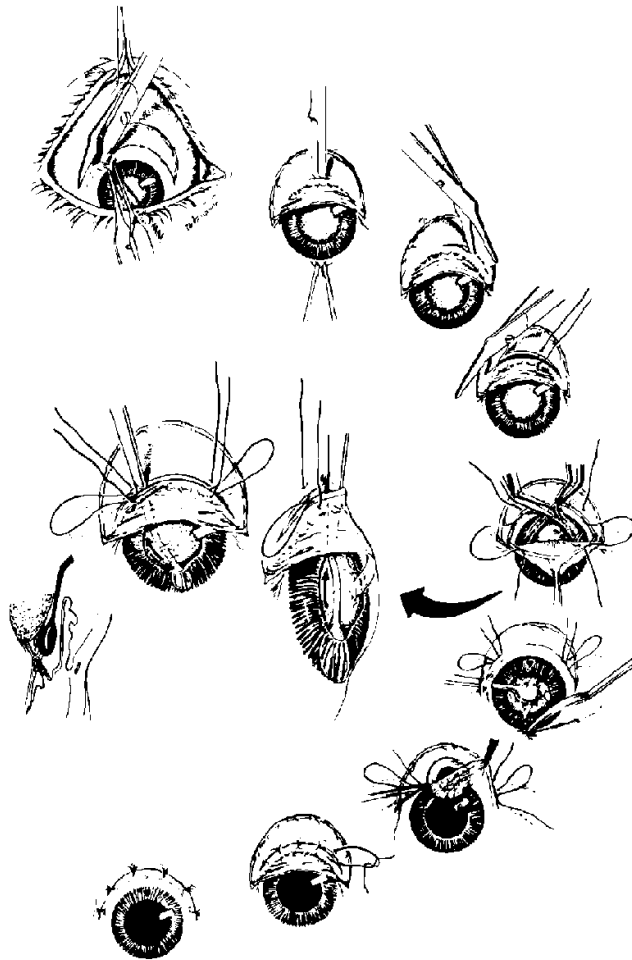


Figure 1-4. Intracapsular lens extraction.

(4) Lens extraction, extracapsular. The anterior capsule is cut, and the lens substance is delivered through the opening in the capsule. The posterior lens capsule

is left in place. Therefore, in extracapsular cataract extraction, the major portion of the lens is removed but some remnants of the lens tissue remain.

c. **Precautions After Surgery.** After surgery, the patient is usually kept at bed rest for a short period, then gradually allowed to ambulate, depending on postoperative conditions. All patients are generally cautioned not to stoop over, lift heavy objects, or strain themselves physically. This warning is maintained during the time when the wound is healing.

1-16. PROCEDURES IN THE TREATMENT OF GLAUCOMA

a. **General.** In glaucoma, there is increased tension or pressure within the eye. Increased intraocular pressure may lead to hardening of the eyeball and blindness. Glaucoma may result from iritis or from trauma.

b. **Operative Procedures.** The various operations used are aimed at reducing tension in the eye by improving intraocular drainage of fluid. The operation performed depends upon several factors, one being the status of the glaucoma (acute, subacute, or chronic).

(1) Iridotomy. This is incision of the iris. The operation is done to create a communication between the anterior and posterior chambers and thus relieve the acute phase of the attack of glaucoma.

(2) Iridectomy. This is excision of part of the iris. A sector of the iris is removed to increase drainage and relieve tension on the eye.

(3) Iridencleisis. This is the formation of an artificial pupil. A fistula is created to provide an outlet for aqueous humor. The iris is incised through an incision at the corneoscleral junction. The free ends are brought out and covered with conjunctival flap.

(4) Trephine. An opening is made by inserting a trephine through the cornea at the corneoscleral junction and cutting through the globe down to the posterior layer of corneoscleral tissue. The trephine is then removed and an iridectomy is performed. The surgeon may perform a trephine operation as the first surgical procedure in the treatment of glaucoma.

(5) Cyclodialysis. A new drainage channel is constructed from the anterior chamber so that aqueous humor drains into the suprachoroidal space. This operation is often done as treatment for glaucoma following cataract extraction.

1-17. PROCEDURES ON THE CORNEA

a. **Repair of Laceration.** A flap of the conjunctiva is used to seal off the tear.

b. **Removal of Foreign Body.** This is done very gently using aseptic technique to avoid secondary infection.

(1) Serious damage to the ocular structures often results from the careless or unskilled removal of foreign bodies from the eye.

(2) The foreign bodies which most commonly cause injury and irritation of the conjunctiva or cornea are dust particles from grinding wheels, cinders, street dirt, gravel, and grains of sand. Foreign bodies such as splinters of wood, metal, or glass which become embedded in or penetrate the eye often cause serious damage.

(3) A foreign body, which is lying on the cornea, is embedded in, or penetrates the eye, is always removed by a medical officer.

c. **Graft of Cornea.** Opaque corneal tissue is excised and healthy corneal tissue of the same size and shape is placed. The operation is done to restore vision by permitting light to enter the eye. An important factor in the success of this surgery is that the donor tissue absolutely be fresh. If opacity (the condition in which light cannot penetrate) has begun to develop in the graft tissue, the success of the operation is doubtful. Eye "banks," similar to other tissue "banks," provide for acquisition, preservation, and transportation of healthy corneal tissue to the hospital where the operation is to be done.

Section II. EAR SURGERY

1-18. GENERAL ANATOMY AND PHYSIOLOGY OF THE EAR

The ear (see figure 1-5) is made up of three distinct divisions: the external ear, the middle ear, and the inner ear. The middle and inner ear structures are situated in the temporal bone cavity.

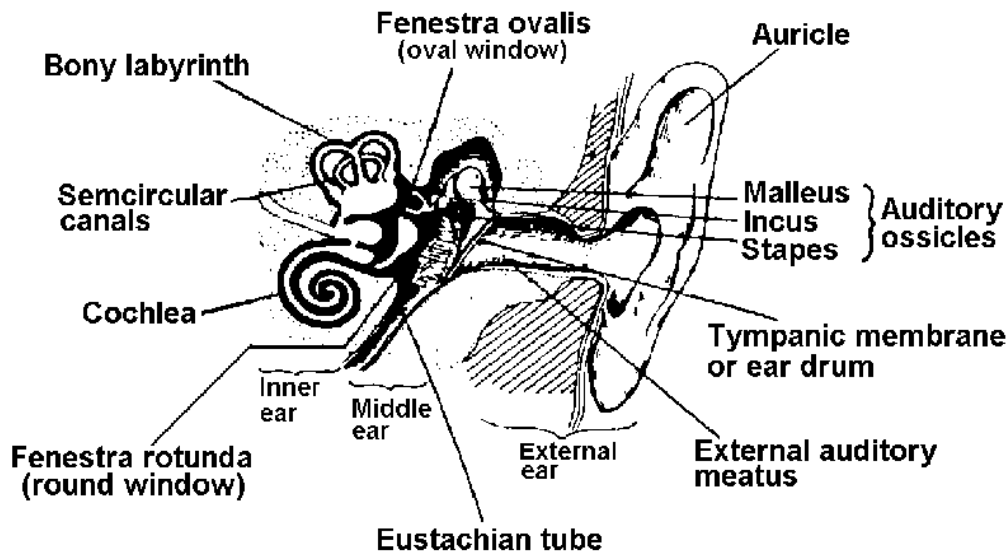


Figure 1-5. Parts of the ear

a. **External Ear.** The external ear consists of an auricle, or pinna, and an external auditory meatus (a tube ending at the tympanic membrane or ear drum). The auricle collects the sound vibrations in the air and sends them through the external canal to the ear drum.

b. **Tympanic Membrane.** The tympanic membrane (see figure 1-6) is a tri-layered membrane stretched across the end of the external meatus. The sound waves come through the meatus and vibrate the membrane.

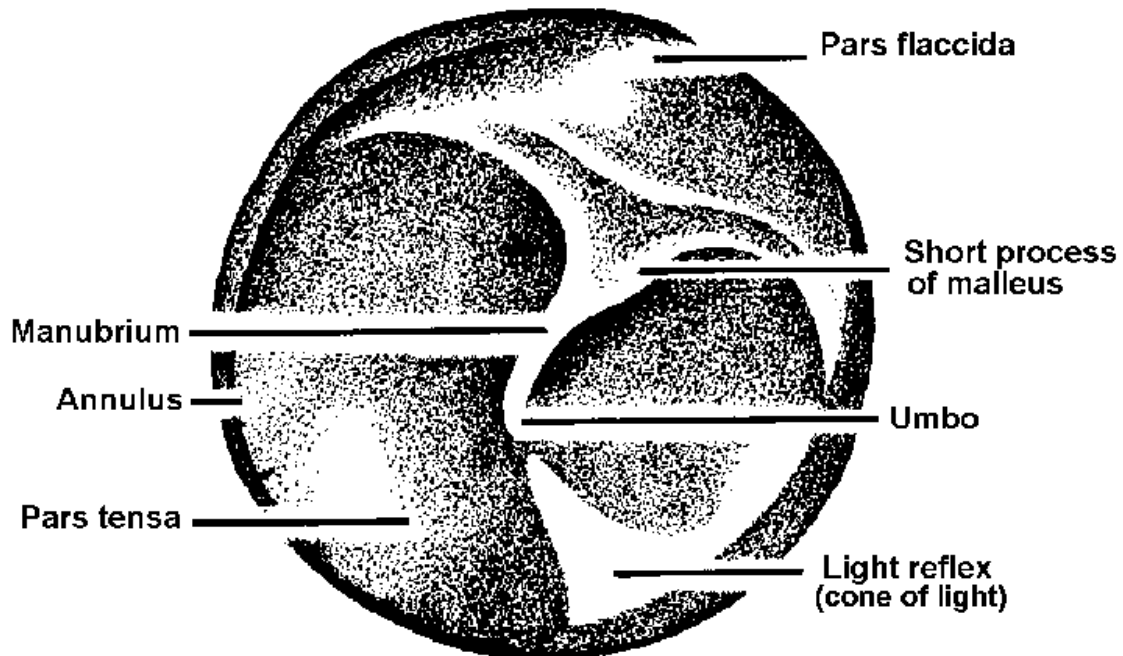


Figure 1-6. Landmarks of right tympanic membrane.

c. **Middle Ear.** Inside the tympanic membrane is a narrow, irregular, oblong, air-conditioned cavity in the tympanic part of the temporal bone. This air-filled space contains three small bones, which transfer the vibrations from the tympanic membrane to the inner ear. Figure 1-7 shows the ossicles of the middle ear.

d. **Inner Ear.** The inner ear is a complex structure located in the petrous portion of the temporal bone. It is made up of two distinct parts, each of which contains its own kind of fluid. Sound vibrations carried by the bones of the inner ear are transferred by way of the oval window to the fluid in the cochlea and received through a fine membrane by the organ of Corti, the delicate neural end organ for sound. A second function of the inner ear is the maintenance of balance, controlled by the movement of fluid in the labyrinth in relation to neuroepithelial cells.

e. **Temporal Bone.** The temporal bone houses the middle and inner ear as well as the mastoid sinuses.

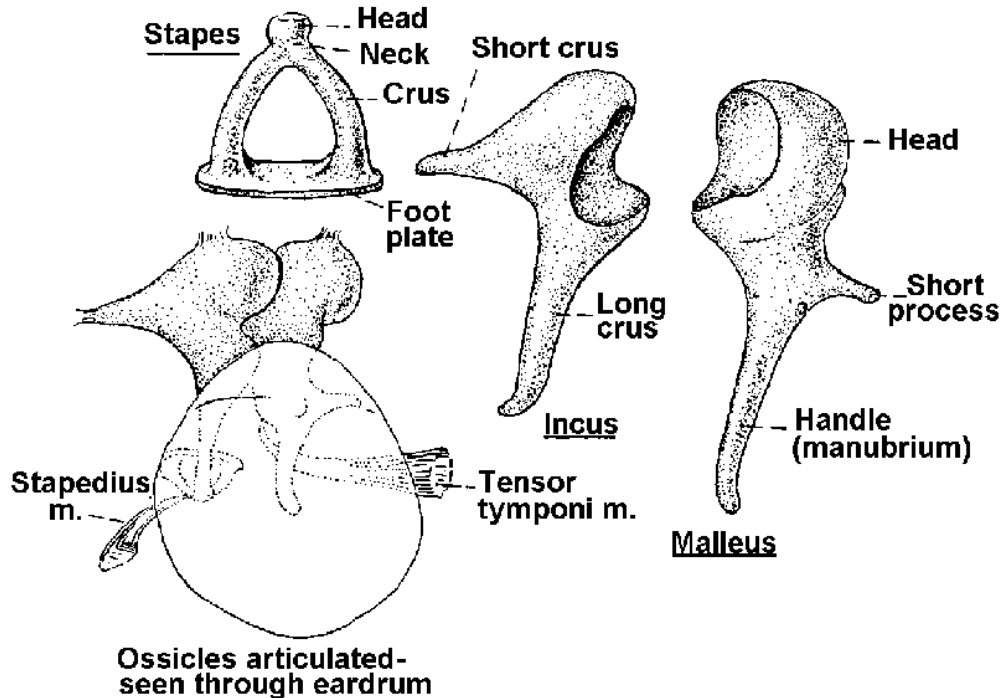


Figure 1-7. Ossicles of the middle ear (separated and articulated).

1-19. EAR OPERATIONS

Ear operations are done on the canals, the middle and inner ears, and the mastoid sinuses (airspaces within the temporal bone). Surgery may be done to correct the effects of trauma or disease, or in an effort to correct hearing disorders.

1-20. PREP FOR EAR SURGERY

a. For operations involving the ear, preparation normally consists of washing the outer ear and surrounding skin with an anti-bacterial detergent and irrigating the canal with a mild antiseptic solution. The canal may also be cleaned with cotton applicators. The hair should be shampooed.

b. Depending upon the approach in surgery and local policy, a 2-inch strip may be shaved at an area of incision. This would also be true in mastoid operations. If hair is to be shaved from the patient's head, the specialist should check local policy regarding the disposition of the hair.

c. Positioning and draping.

(1) Quietness and immobility of the patient are most important in otological (ear) surgery. The head must be carefully immobilized by whatever method is prescribed for a particular procedure. The patient is to be placed on his back with his

head turned to the side, with the affected ear up. Great care must be taken in alignment of the patient, especially if the procedure is time consuming.

(2) In the presence of infection, disposable sheets and towels should be used. An opening can be readily made with scissors in the sterile sheet or towel to expose the operative site. A standard ear pack is used.

(3) Three towels are folded lengthwise and placed around the operative site. The first one is placed horizontally above the ear, the second towel is placed diagonally on the outer prepared skin area surrounding the ear, and the third vertically in front of the meatus. A folded fenestrated sheet is unfolded over the patient and table, with the operative site in view through the opening.

(4) The draped tables with sterile instruments and the operating microscope are positioned around the patient. For example, if the operation involves the left ear, the sterile instrument table is placed near the left side of the operating table. The scrub usually sits or stands near the instrument table and passes the instruments to the surgeon in such a manner that he does not have to turn away from the operative microscope.

(5) All safeguards should be taken to prevent explosive hazards. This is most important because there are many electrical appliances in use during otological surgery.

d. Anesthesia for ear surgery may be local or general depending upon the severity of the surgery to be performed and the age of the patient.

e. The dressing applied following surgery is usually one of two types. For internal canal work, an ear wick may be inserted. For surgery on the mastoid sinuses or any posterior approach, a large compression type dressing commonly referred to as a mastoid dressing is applied.

1-21. INSTRUMENTS AND SUPPLIES

Check the surgeon's card carefully, and make sure that all instruments and equipment are assembled. The operating microscope, suctioning equipment, and drill are often required. All equipment must be in working order. Since the operating microscope is used in such close proximity to the surgical wound, it is draped with disposable microscope drapes before use. Electric cautery equipment is also sometimes needed.

1-22. INCISIONAL APPROACHES

a. The endaural (vertical) incision frequently is used for temporal operations, except for simple mastoidectomy. The first incision extends from the superior meatus

wall, and the second extends directly upward to a point between the meatus and the upper edge of the auricle, where the two incisions join.

b. The high posterior incision may be used in operations on infants or young children. The incision is placed at a higher posterior level than is the endaural incision, thereby avoiding possible damage to the facial nerve.

c. The postaural incision may be used to expose the mastoid process. It follows the curve of the postaural fold, beginning at the upper attachment of the auricle and continuing behind the postaural fold downward to the tip of the mastoid process.

d. For stapes surgery, a circumferential incision is made in the posterior half of the canal, starting at the inferior aspect of the annulus and ending posterior to the short process of the malleus.

e. For myringotomy, a circumferential (posteroinferior) incision is made. It provides for wide drainage and removal of pus or fluid under pressure from the middle ear.

1-23. MYRINGOTOMY

a. **General.** Myringotomy is an incision through the tympanic membrane. This may be done when an inner ear infection produces pus that is causing undue pressure on the membrane. It may also be done to correct hearing loss due to fluids in the middle ear.

b. **Preparation of the Operating Room.** Sterile instruments are set up in accordance with local policy and the surgeon's preference. Non-instrument items in the setup include cotton-tipped applicators, cotton (for plugging the canal after surgery), and culture tubes.

c. **Operative Procedure.**

(1) Through microscopic visualization, the aural speculum is inserted in the canal. Using a sharp myringotomy knife, a small curved incision is made in the posteroinferior quadrant or the pars tensa, and the thickened membrane is cut.

(2) A culture is taken to determine the type of organisms present.

(3) Pus and fluids are suctioned out.

(4) A plastic tympanotomy tube prosthesis is usually put into place.

1-24. RADICAL MASTOIDECTOMY

a. **General.** Radical mastoidectomy involves the removal of the mastoid air cells, the tympanic membrane, the involved malleus, incus, chorda tympani, and mucoperiosteal lining which converts the middle ear and the mastoid into one cavity. This procedure may be used to treat a chronic otitis media (inflammation or infection of the middle ear) that has spread into the mastoid air cells, and when skin from the external auditory canal has grown into the middle ear (cholesteatoma) where it acts as a foreign body. Radical mastoidectomy may also be done to provide adequate exposure in the treatment of facial nerve decompression to drain an extradural abscess in the bony labyrinth.

b. **Preparation of Operating Room.** This requires an extensive setup of instruments and other sterile items. These are set up in the appropriate sizes and numbers, as prescribed locally.

c. **Operative Procedure.**

(1) An endaural or postaural incision is made using a Bard-Parker knife. Bleeding vessels are clamped and ligated. With a second knife, the periosteum (connective tissue over bone) is incised and freed to form a flap. The wound is retracted with a self-retaining retractor.

(2) The meatus flap is cut, exposing the mastoid area by means of a circumferential knife, narrow periosteal elevator, and curved scissors.

(3) The mastoid antrum is exposed. By means of round cutting burrs attached to an electric drill, the bone of the outer cortex is removed. The osseous metal walls are removed with rongeurs or burrs. The wound is irrigated and suctioned. Cotton pledgets are used for sponging the operative site.

(4) The thin bridge of bone between the meatus and antrum is removed with angular dissectors and fine currettes.

(5) The tympanic membrane, malleus, incus, and mucoperiosteal lining of the middle ear cavity are excised by means of stapes instruments, as for a stapes operation.

(6) The tympanic cavity is cleaned. The wound is closed with sutures. A musculo-plasty may be done by taking a strip of temporalis muscle from above the ear and placing it in the mastoid cavity. In time, the skin grows over the muscle.

(7) The mastoid cavity is usually packed with a strip of 1/2 x 8 inch gauze packing that has been impregnated with petrolatum or an antibiotic ointment. The wound is closed.

(8) The ear dressing is applied, including a shaped ear pad. Fluffed 4 x 8 inch gauze sponges are placed around and behind the affected ear and then flat compresses over the affected ear. A gauze bandage is applied in a particular manner to hold the dressings in place and avoid pressure.

1-25. SIMPLE MASTOIDECTOMY

a. **General.** Simple mastoidectomy involves the removal of the air cells of the mastoid process without disturbing the contents of the middle ear. It may be done occasionally to treat acute empyema (accumulation of pus) of the mastoid, but has been made almost obsolete by antibiotics.

b. **Operative Procedure.** A postural or endaural incision is made. Perform procedures for a radical mastoidectomy as stated in paragraphs 1-24c(1), (2), (3), and (6).

NOTE: A modified radical mastoidectomy may also be done in which the middle ear is not involved, but in which the thin bridge of bone between the external canal wall and antrum is removed.

1-26. TYMPANOPLASTY OPERATIONS

Tympanoplasty involves a large variety of reconstructive operations of the middle ear designed to restore or improve hearing in patients with middle ear or conductive-type hearing loss. In various operations of this type, tissue grafts of different kinds are often used.

Section III. NOSE SURGERY

1-27. OPERATIONS ON THE NOSE

Operations on or through the nose (see figure 1-8) may be required to correct results of trauma to the nose and related structures; to correct deformities that interfere with breathing, such as deviated nasal septum, hypertrophy of the turbinates, and polyps or other neoplasms; and to relieve the effects of sinusitis.

1-28. ANATOMY AND PHYSIOLOGY OF THE NOSE

The nose is divided into the prominent external nose and the internal nose known as the nasal cavity. The chief purpose of the nose is the preparation of air for use in the lungs.

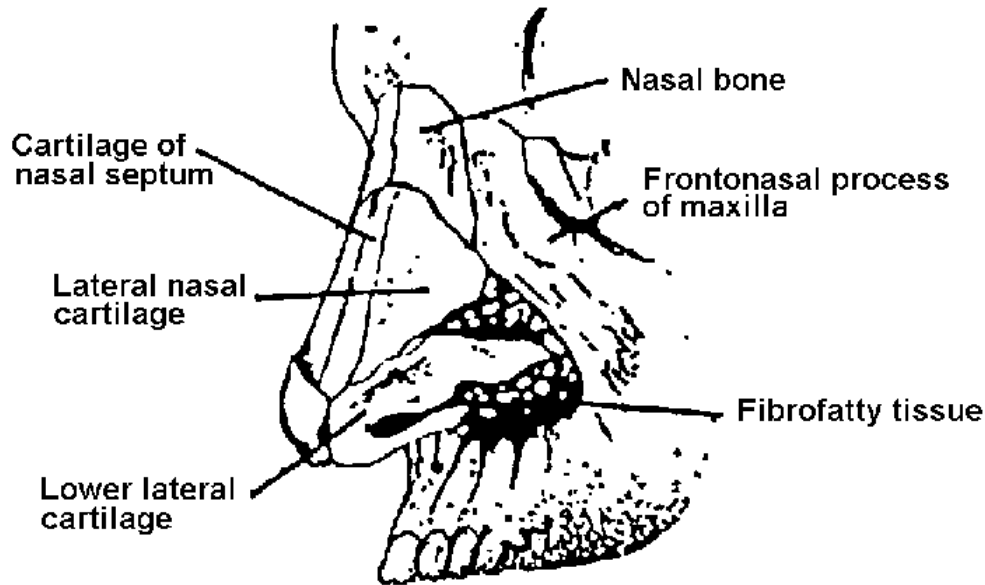


Figure 1-8. Nasal skeletal framework.

a. External Nose.

(1) The external nose projects from the face. The upper portion of the nose is formed by the nasal bones and the frontal process of the maxillae. The lower portion is formed by a group of nasal cartilages and connective tissue covered with skin. The nostrils and the tip of the nose are shaped by the major alar cartilages. The nares are separated by the columella, which is formed by the lower margin of the septal cartilage, the medial parts of the major alar cartilages and the anterior nasal spine, all of which are covered by skin.

(2) The nasal septum is composed of three structures: the nasal cartilage, the vomer bone, and the perpendicular plate of the ethmoid bone. The septum is covered by mucous membrane on either side. The deviated or fractured septum may be repaired surgically by mobilization of the fracture or removal of the deformed cartilage or bone.

b. Internal Nose.

(1) The internal nose or nasal cavity is divided into two parts at its midline by the nasal septum. The nasal cavity communicates with the outside by its external openings, called the anterior nares. The nares open into the nasopharynx behind through the choanae. The nasal cavity is also associated with each ear by means of the eustachian tube and with the paranasal air sinuses (see figure 1-9) (frontal, maxillary, ethmoid, and sphenoid) via their respective orifices (meatuses). The nasal cavity communicates with the conjunctive through the nasolacrimal duct as well.

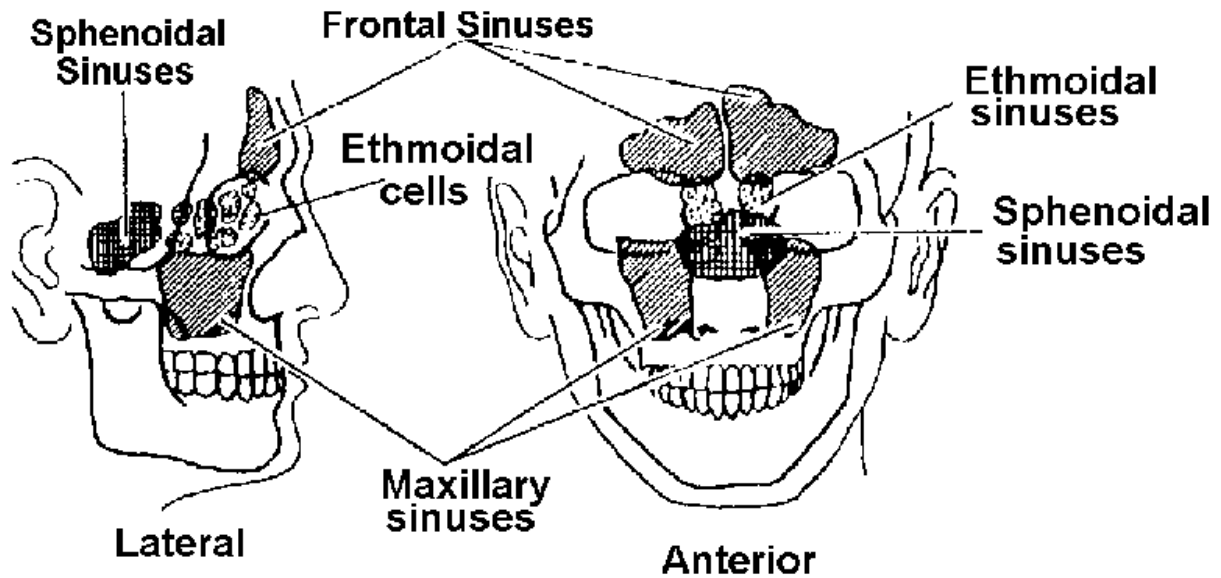


Figure 1-9. The paranasal sinuses (lateral and anterior aspects).

(2) The nasal cavity is separated from the lingual cavity by the hard and soft palates and from the cranial cavity by the ethmoid bone. The nasal cavity is held together by periosteal covering and by perichondrium, which extends over the cartilages.

c. Turbinate Bones and Sinuses.

(1) The turbinate bones of the nasal structure are arranged one above the other, separated by grooves (the meatuses). These act as drainage passages of the accessory sinuses and are known as the sphenothmoidal recess and the superior, middle, and inferior meatus, respectively.

(2) The nasal sinuses serve as air spaces and communicate with the nasal cavity via the meatuses. Anteriorly, on each side of the skull, the frontal sinus, the anterior ethmoid cells, and the maxillary sinus (antrum of Highmore) drain into the middle meatus; posteriorly, the ethmoid cells and the sphenoid sinus drain into the superior meatus and the sphenothmoidal recess. A passageway for the flow of air is provided by the irregular air spaces present between these structures. Because of their shape, the air is forced to flow in thin airwaves.

d. Nerve and Blood Supplies.

(1) The sensory nerve supply of the nasal cavity is derived from the trigeminal nerve.

(2) The nose and sinuses receive their blood supply from branches of the internal maxillary artery. There are masses of communicating veins below the epithelial

layer of the turbinated bones, and those veins lying just beneath the mucosa anastomose (communicate) freely. Dilatation of the superficial veins may cause the turbinated bone mucosa to swell, whereas contraction of these vessels may cause the mucosa to shrink.

1-29. PREP, POSITION, DRAPE, ANESTHESIA, AND LIGHTING

All procedures performed prior to the start of surgery must be explained to the patient to avoid fright and apprehension.

a. The male patient shaves his face prior to surgery. The immediate preoperative prep may include clipping the hairs within the nostrils using small tenotomy scissors. The specialist is to coat the blades of the scissors with a film of vaseline so that the patient will not aspirate the nasal hairs. The patient's face is then washed with antibacterial detergent and sponged dry. His eyes should be protected during this procedure with damp gauze compresses. No solution is applied inside the nose.

b. The patient is placed in either the supine position or the reclining position. For procedures done using local anesthesia, the reclining position enables the patient to expectorate any fluid collecting in his mouth and thus helps keep the operative area free from drainage.

c. A large drape sheet is placed lengthwise over the front of the patient and is secured bib-fashion. Suction tubing is pinned to the sheet. Sterile towels may be wrapped around the patient's head and secured with towel forceps, leaving his face exposed but his eyes covered. Another method of draping the head is to cover it with a small fenestrated sheet through which the nose and mouth are exposed.

d. Local anesthesia is usually employed for nasal surgical procedures on adults. The method of administration is a combination of topical (nasal packs) and infiltration anesthesia. The specialist assists the surgeon as necessary in packing the nose. Use of local anesthesia enables the patient to cooperate with the surgeon and avoids the complication of vomiting.

e. Illumination is provided by either of two methods: the electric head lamp or the overhead light. The two devices are sometimes used in conjunction.

1-30. SEPTECTOMY, OR SUBMUCOUS RESECTION

a. **General.** Septectomy, or submucous resection (SMR) deviations of the nasal septum may result from faulty development of the septum or from injury to the nose. The patient's symptoms include inadequate or difficult nasal breathing or obstruction of nasal drainage. Septal deviations tend to cause sinus disease and the formation of polyps. The operation consists of removing the bent parts of the nasal septum that lie between the flaps of mucous membrane to establish a straight partition.

b. Preparation of the Operating Room.

(1) The setup of sterile instruments and other equipment is done as prescribed locally. Gauze packing is included for use as a pressure dressing.

(2) The room is darkened before the patient arrives. The surgeon usually uses an electrical head lamp that will focus a beam into the nostrils. The circulator is to connect and carefully check all special lighting equipment prior to the start of the procedure.

(3) This operation is generally done with the patient under local and/or topical anesthesia. Before the patient arrives, the operating table is made into a reclining chair by use of a foot-piece and pillows placed for protection of feet from pressure and relief of strain on vessels and tendons of the lower extremities. The reclining chair is adjusted to meet the physical characteristics and comfort of the patient. The table is raised or lowered to accommodate the surgeon.

c. Preparation of the Patient.

(1) In some cases, the hair of the nostrils may be clipped with fine, curved scissors. Sterile mineral oil drops or an antibiotic ointment may be put in the eyes of the patient to protect them from prepping solutions. The face is scrubbed with a mild soap and water. The face prep and draping of the patient is done prior to anesthetizing. The circulating nurse should observe changes in the vital signs of the patient. When cocaine or some similar narcotic agent is used, a thiopental (Pentothal[®]) sodium setup and oxygen equipment should be in the room. **Topical medications that have changed color should not be used.** The amount of the topical agent dispensed for the operation must be recorded on the anesthesia record and on the pharmacy's narcotic form.

(2) The patient is draped with sterile towels and sheets as follows:

(a) Place the small sheet with two towels on top of it over the head of the table and under the head of the patient.

(b) Bring the uppermost towel around the head, including the hairline.

(c) Secure the ends of the uppermost towel with a towel forceps and tuck the free ends under the patient's head.

(d) Drape a large sheet over the patient, bringing its upper end up to the chin.

(e) Place the tray with the instruments in position for the surgeon.

(f) Adjust the lighting system.

- (g) Record the vital signs of the patient.
- (h) Reassure the patient if awake.

d. **Operative Procedure.** The operative procedure will vary with the individual surgeon. A general review of most procedures is as follows:

(1) The nostril is opened with a speculum. An incision is made through the mucoperichondrium and mucoperiosteum of the septum with a knife, blade number 15. The tissues are separated and elevated, using a Freer knife.

(2) The cartilage is incised with a knife, and the mucous membrane is elevated with a septal elevator; part of the septal cartilage is excised with a Ballenger knife; deviated cartilage and bony, thickened structures are removed with a septum punch and a nasal cutting forceps.

(3) The mucous membrane is freed from the bony septal base by means of a chisel, gouge and mallet, or punch forceps. Bleeding is controlled by cotton sponges; suctioning is used to expose the field.

(4) The perpendicular plate of the ethmoid may be removed, as well as the vomer, by means of the S-retractor, chisel and mallet, and a suitable septum-cutting forceps.

(5) The incision may or may not be sutured with silk #3-0 fused to a small 1/2-circle taper-point needle on a Crile needle holder.

(6) Nostrils are packed with petrolatum gauze in order to keep the septal flaps in a midline position. The face is cleansed with both moist and dry compresses.

e. **Specimens.** Excised tissue is processed as a specimen.

1-31. OTHER NASAL OPERATIONS

The specialist assigned to scrub or circulate for the operations duties are similar to those described for submucous resection. The specialist is to check local policy carefully concerning instruments, sutures, and other items in the setup for the operation to be performed.

a. **Excision of Nasal Polyps.** Polyps are soft, benign tumors of the nasal mucosa caused by chronic nasal allergy (see figure 1-10).

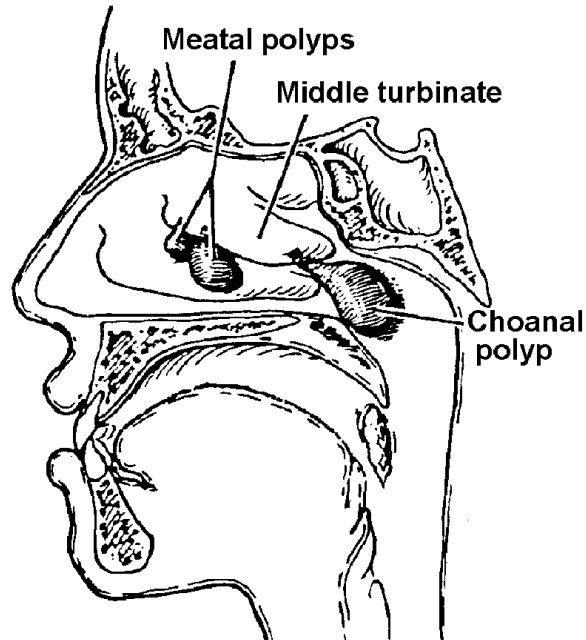


Figure 1-10. Nasal polyps.

(1) Operation. Polyps that arise from the border of the middle turbinate may be removed by means of a submucous resection setup, using a nasal snare. Polyps that arise above this level may involve a sinus cavity, thus necessitating surgery of the sinus. In this event, the instruments and other setup are determined by the specific sinus cavity involved.

(2) Indications. The pressure exerted by nasal polyps results in obstruction to the passage of air through the nostrils. The obstruction may lead to a condition of chronic infection of the nose and give rise to frequent attacks of nasopharyngitis. The infection may extend also into the nasal sinuses, thus obstructing drainage from the affected sinus. The patient suffers pain in the region of the sinus involved. Treatment of the condition is excision of the polyps.

b. **Turbinectomy.** Turbinectomy is the surgical removal of hypertrophied portion of a turbinate bone.

(1) Hypertrophy of the turbinate prevents adequate breathing and drainage through the nose and produces painful pressure against the floor of the nose. Treatment is the removal of the hypertrophied turbinate.

(2) Excision of the hypertrophied portion of the turbinate is done using a setup as described for removal of nasal polyps.

c. Intranasal Antrostomy (Antral window).

(1) General. This procedure involves making an opening in the lateral wall of the nose under the inferior turbinate. It is done to relieve headaches, edema, infection, or swelling of the membranes lining the sinuses.

(2) Operative procedure. After prep and anesthesia, a postnasal plug is inserted. The inferior turbinate is elevated superiorly by means of a large elevator or tonsil dissector. An opening is made into the maxillary sinus beneath the inferior turbinate by means of a gouge, perforator, or antrum cannulae. The opening is enlarged with cutting forceps and antrum punches. Accessory polyps and degenerate mucosa are removed with a snare, septum forceps, and suction. The sinus is irrigated with saline solution by means of a Thornwald irrigator and suction apparatus; the sinus is packed with petrolatum impregnated iodoform gauze, and the face is cleaned and dried.

d. Radical Antrostomy (Caldwell-Luc Operation).

(1) General. This procedure involves an incision into the canine fossa of the upper jaw and exposure of the antrum for removal of bony diseased portions of the antral wall and contents of the sinus, or establishment of drainage by means of a counteropening into the nose through the inferior meatus.

(2) Operative procedure.

(a) The upper lip is elevated with a retractor, and a transverse incision is made in the gingivolabial sulcus just above the teeth; the incision is carried down to the underlying bone. Periosteum and soft tissue are elevated with dissectors and periosteal elevators.

(b) The thin bony plate is perforated with a gouge, the antrum is entered, and its opening is enlarged with nasal rongeurs. The anterior angle of the sinus may be opened by enlarging the window with Jansen-Middleton septum-cutting forceps, double-action rongeurs, and Kerrison forceps.

(c) The mucous membrane of the antrum is removed with Coakley or Myles angled currettes.

(d) Nasoantral drainage may be established by removal of a portion of the nasoantral wall below the inferior turbinate by means of cutting forceps and rasps.

(e) The antrum is packed with petrolatum gauze.

(f) The labial incision may or may not be sutured. The face of the patient is cleaned and dried.

e. **Frontal Sinus Operation.**

(1) General. This procedure involves making an incision through the eyebrow of the affected side and through the anterior wall and floor of the frontal sinus for removal of the diseased tissue, cleansing of the sinus cavity, and drainage. It may be made necessary in acute frontal sinusitis with persistent headaches and edema of the upper lid when other modes of therapy have failed.

(2) Operative procedure.

(a) An incision is made over the affected frontal sinus, extending from the base of the nose through the eyebrow as far as the supraorbital notch. A self-retaining retractor, hook retractor, knife, sponges, fine hemostats, fine ligatures, and suction set are needed.

(b) Either the anterior wall of the frontal sinus or the floor of the sinus is opened by means of dental burrs, chisel, mallet, gouges, septum-cutting forceps, curettes, and nasal forceps. Drainage is established by either the nasofrontal duct or the insertion of drains.

(c) An ethmoidal incision is made behind the nasal process of the superior maxillary bone with a chisel and mallet. The lacrimal duct is identified and preserved. Ethmoid cells are curetted.

(d) A Penrose drain is introduced; the external wound is approximated with fine silk sutures and dressing applied. The patient's face is cleaned and dried.

f. **Ethmoidectomy.**

(1) General. This is for removal of the diseased portion of the middle turbinate, opening and removal of ethmoid cells, and removal of diseased tissue in the nasal fossa through a nasal approach or external approach. It reduces the many celled ethmoid labyrinth into one large cavity to ensure adequate drainage and aeration.

(2) Operative procedure. For the nasal route, the procedure is similar to intranasal antrostomy described previously. For the external route, the procedure is similar to the frontal sinus operation.

g. **Sphenoidectomy.**

(1) General. This involves making an opening into one or both of the sphenoid sinuses by the intranasal or external ethmoidectomy approach. It is difficult to visualize the cavity of the sphenoid sinus because of its depth. Surgery of the sphenoid sinus is usually done intranasally or through an external ethmoidectomy approach.

(2) Operative procedure. This is the same as for intranasal antrostomy.

h. Fracture of the Nose.

(1) General. This procedure involves the manipulation and mobilization of fractured nasal bones and cartilages. Early reduction is important.

(2) Operative procedure. A rubber-covered narrow forceps is inserted into the nostril; the nasal bones are elevated and molded into place by external manipulation.

Section IV. THROAT, TONGUE, AND NECK SURGERY

1-32. THROAT OPERATIONS

Surgery of the throat (see figure 1-11) may be done to halt or correct the effects of trauma or disease, including neoplasm. Structures included in throat surgery are the pharynx, larynx, trachea, tongue, palate, tonsils, and adenoids.

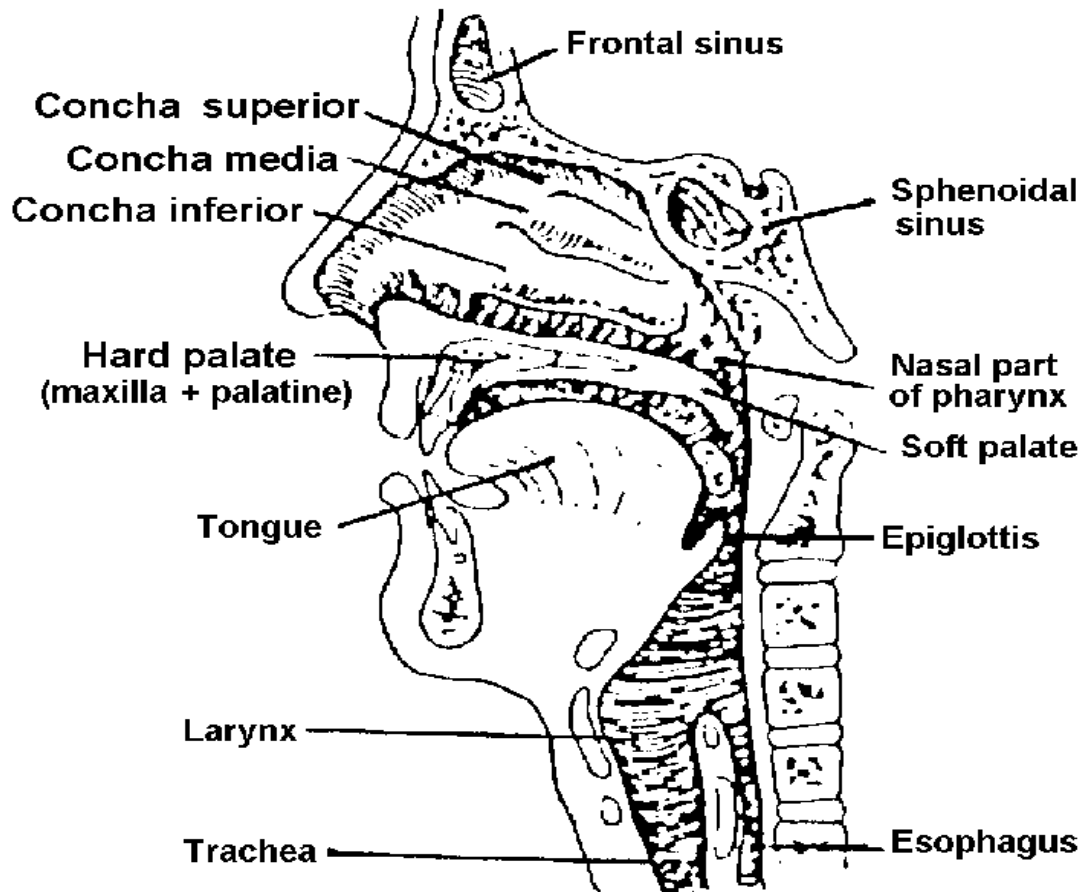


Figure 1-11. Sagittal section of the face and neck.

1-33. ANATOMY AND PHYSIOLOGY OF THE THROAT AND NECK

The word throat refers to those structures of the neck in front of the vertebral column, including the mouth, tongue, pharynx, tonsils, larynx, and trachea.

a. **The Mouth.** The mouth extends from the lips to the anterior pillars of the fauces. The portion of the mouth outside the teeth is known as the buccal cavity and that on the inner side of the teeth as the lingual cavity. The tongue occupies a large portion of the floor of the mouth. The hard and soft palates form the upper and posterior boundaries of the oral cavity, separating it from the nasal cavity and the nasopharynx. The soft palate emerges from the posterior border of the hard palate to form the uvula, a fingerlike movable projection. On either side, the uvula is adjacent to the base of the tongue anteriorly and the pharynx posteriorly.

b. **The Pharynx.**

(1) The pharynx serves as a channel for both the digestive and respiratory systems. It is situated behind the nasal cavities, mouth, and larynx. The food and air passages cross each other in the pharynx. The pharynx is a funnel-shaped structure, wide above and narrower below, about 12 cm in length. It is composed of muscular and fibrous layers and lined with mucous membrane. It is associated above with the sphenoid and the basilar part of the occipital bone. Below, it joins the esophagus. Seven cavities communicate with the pharynx: the two nasal cavities, the two tympanic cavities, the mouth, the larynx, and esophagus. The cavity of the pharynx may be subdivided from above downward into three parts: nasal, oral, and laryngeal. Infection may spread from the pharynx to the middle ear via the auditory tube. This auditory tube can be catheterized through the nostril.

(2) The nasopharynx communicates with the oropharynx through the pharyngeal isthmus, which is closed by muscular action during swallowing. The oropharynx and the laryngopharynx cannot be closed by muscular action during swallowing. The oropharynx and the laryngopharynx cannot be closed off from each other; both service respiratory and digestive functions.

(3) The pharynx is made up of three groups of constrictor muscles. Each muscle fits within the one below, and each inserts posteriorly in the median line with its mate from the opposite side. The constrictor muscles provide constriction of the pharynx for dilatation. Between the origins of the constrictor muscle groups, there are so-called intervals through which pass ligaments, nerves, and arteries. The recurrent laryngeal nerve is closely associated with the lower portion of the pharynx.

c. **The Tonsils.**

(1) The tonsils are situated one on each side of the oropharynx, lodged in a tonsillar fossa that is attached to folds of membrane containing muscle. One pair, the palatine tonsils, is the only lymphatic organ covered with stratified squamous epithelium.

The lateral surface of each tonsil is usually covered with a fibrous capsule. The anterior and posterior tonsillar pillars join to form a triangular fossa, with the posterior lateral aspects of the tongue at its base. The so-called palatine tonsils are lodged in each fossa. The adenoids (pharyngeal tonsil) are suspended from the roof of the nasopharynx and consist of an accumulation of lymphoid tissue.

(2) The arteries of the tonsils enter the upper and lower poles. The tonsils are supplied with blood primarily by the tonsillar branch and the ascending palatine branch of the facial artery (branches of the external carotid artery). The external carotid artery on each side lies behind and lateral to each tonsil. The nerves supplying the tonsils are derived from the middle and posterior palatine branches of the maxillary and glossopharyngeal nerves.

d. **The Larynx and Associated Structures.**

(1) The larynx.

(a) The larynx is located at the upper end of the respiratory tract and is situated between the trachea and the root of the tongue, at the upper front part of the neck. The larynx has three main functions: a passageway for air, a valve for closing off air passages from the digestive system, and the pharynx, and a voice box on which sound and speech depend on to a degree.

(b) The larynx is a cartilaginous box, situated in front of the fourth, fifth, and sixth cervical vertebrae. The upper portion of the larynx is continuous with the pharynx above, and its lower portion joins the trachea. The skeletal structure provides for patency of the enclosed airway. The complex muscle action and arrangement of tissues within the structure provide for closure of the lumen for protection against trauma and entrance of foreign bodies and for phonation.

(2) Cartilages. The skeletal framework of the larynx consists of cartilages and membranes. There are nine separate cartilages-- three of them single and six arranged in pairs. The main cartilages of the larynx include the thyroid, cricoid, epiglottis, two arytenoid, two corniculate, and two cuneiform. The thyroid cartilage (Adam's apple) forms the anterior portion of the voice box. The cricoid cartilage, which resembles a signet ring, rests beneath the thyroid cartilage and within the laryngotracheal space. The epiglottis is a slightly curled, leaf-shaped, elastic fibrous membrane. It is prolonged below into a slender process, attached in the midline to the upper border of the thyroid cartilage. When the cricothyroid muscle contracts, it pulls the thyroid cartilage and the cricoid cartilage, thereby tightening the vocal cords and, if unopposed, closing the glottis. The arytenoid cartilages, which rest above the signet ring portion of the cricoid cartilage, support the posterior portion of the true vocal cords.

(3) Laryngeal ligaments.

(a) The extrinsic ligaments of the larynx are those connecting the thyroid cartilage and epiglottis with the hyoid bone and the cricoid cartilage with the trachea. The intrinsic ligaments of the larynx are those connecting several cartilages of the organ to each other. They are considered the elastic membrane of the larynx.

(b) The mucous lining of the larynx blends with the fibrous tissue to form two folds on each side of the larynx. The upper set are known as the false cords. The lower set are called the true vocal cords because they are primarily concerned with the speaking voice and protection of the lower respiratory channels against the invasion of food and foreign bodies.

(4) Laryngeal muscles.

(a) The laryngeal muscles perform two distinct functions. There are muscles (extrinsic type) that open and close the glottis and those (intrinsic type) that regulate the degree of tension of the vocal cords.

(b) It should be noted that the spoken voice also depends on the sphincter action of the soft palate, tongue, and lips. The muscle action of the larynx permits the glottis to close either voluntarily or involuntarily by reflex action. The closure of the inlet by this mechanism protects the respiratory passages. The closure of the glottis and the action of the vocal cords are precisely coordinated to produce the spoken voice.

(c) Two branches of the vagus nerve supply the intrinsic muscles. The recurrent laryngeal nerve branch of the vagus nerve is the important motor nerve of the intrinsic muscles of the larynx. The sensory nerve, which is derived from the branches of the superior laryngeal nerve, supplies the mucous membrane of the larynx.

(d) When both the recurrent laryngeal nerves become divided or paralyzed, the glottis remains closed so tightly that air cannot be drawn into the lungs. As a lifesaving measure, an endotracheal or tracheostomy tube is inserted immediately.

(e) The larynx derives its blood supply from the branches of the external carotid and subclavian arteries.

e. **Trachea.** The trachea, a cylindrical tube about 15 cm in length and from 2 to 2.5 cm in diameter, begins in the neck and extends from the lower part of the larynx, on a level with the sixth cervical vertebra, to the upper border of the fifth thoracic vertebra. The tube descends in front of the esophagus, enters the superior mediastinum, and divides into right and left main bronchi. The trachea is composed of a series of incomplete rings of hyaline cartilage. The carina is a ridge on the inside at the bifurcation of the trachea. It is a landmark during bronchoscopy and separates the upper end of the right main branches from the upper end of the left main branches of

the bronchi. Branches given off from the arch of the aorta--the brachiocephalic (innominate) and left common carotid arteries--are in close relation to the trachea. The cervical portion of the trachea is related anteriorly to the sternohyoid and sternothyroid muscles and to the isthmus of the thyroid gland.

f. Salivary Glands.

(1) The salivary glands consist of three paired glands: the sublingual, submaxillary, and parotid. They communicate with the mouth and pour their secretions into its cavities. The combined secretion of all these glands is termed saliva. The salivary glands consist of tissue found in the mucosa of the cheek, tongue, palate, floor of the mouth, pharynx, lip and paranasal sinuses. A tumor of a salivary gland may occur in any of these structures.

(2) The external carotid artery supplies the salivary glands and divides into its terminal branches: the internal maxillary and superficial temporal. The superficial temporal and internal maxillary veins unite to form the posterior facial vein.

(3) The sublingual gland lies on the undersurface of the tongue beneath the mucous membrane of the floor of the mouth at the side of the frenulum linguae, in communication with the sublingual depression on the inner surface of the mandible. It is supplied with blood from the submental arteries. Its nerves are derived from the sympathetic nerves. The many tiny ducts of each gland separately enter into the oral cavity on the sublingual fold.

(4) The submandibular gland lies partly above and partly below the posterior half of the base of the mandible and on the mylohyoid and hyoglossus muscles. This gland is closely associated with the lingual veins and the lingual and hypoglossal nerves. The external maxillary artery lies on the posterior border of the gland. Its duct (Wharton's duct) enters the mouth at the frenulum of the tongue.

(5) The parotid gland, the largest of the salivary glands, lies below the zygomatic arch in front of the mastoid process and behind the ramus of the mandible. This gland is enclosed in fascia, attached to surrounding muscles, and divided into two parts--a superficial and a deep portion--by means of the facial nerve. The parotid duct (Stensen's duct) pierces the buccal pad of fat and the buccinator muscle, finally opening into the oral cavity opposite the crown of the upper second molar tooth. The superficial temporal artery and small branches of the external carotid arise in the parotid gland behind the neck of the mandible.

g. General Structures of the Neck.

(1) The general topography of the organs lying in front of the prevertebral facial has been described. A layer of deep cervical fascia surrounds the neck like a collar and is attached to the trapezius and sternocleidomastoideus (sternocleidomastoid) muscles. In front of the neck, the deep fascial layer is attached to the lower border of the mandible.

(2) The pretracheal fascia of the neck lies deep in the strap muscles (sterno-thyroid, sternohyoid, and omohyoid) and partially encloses the thyroid gland, trachea, and larynx. The pretracheal fascia is pierced by the thyroid vessels. It fuses with the front of the carotid sheath on the deep surface of the sternocleido-mastoid. The carotid sheath consists of a network of areolar tissue surrounding the carotid arteries and vagus nerve.

(3) Laterally, the carotid sheath is fused with the fascia on the deep surface of the sternocleidomastoideus; anteriorly, it is fused with the middle cervical fascia along the lateral border of the sternothyroideus muscle. Lying between the floor and roof of this triangular formation of muscles are the lymph glands and the accessory nerve. Arteries and nerves traverse and pierce this triangle.

h. Lymphatic System of the Neck. The lymph glands of the neck are closely associated with the salivary glands and the lymph plexus. The submaxillary nodes, located in the submaxillary triangle, drain the cheek, side of the nose, upper lip, side of the lower lip, gums, side of the tongue, and medial palpebral commissure. Lymph from the facial and submental nodes also drains to these glands. The superficial cervical nodes, following the external jugular vein, drain the ear and parotid area to the superior deep cervical nodes. The cervical nodes are in close contact with the larynx, thyroid gland, nasal cavities, ear, nasopharynx, palate, esophagus, and skin and muscles of the neck.

1-34. PREP, POSITION, DRAPE, AND ANESTHESIA

a. The face is prepped with an antibacterial detergent, as for surgery of the nose. The inside of the mouth is not prepped. When the approach is through the lower throat, the area from the jaw line to the upper clavicle is prepped.

b. The supine position is usually employed during surgery of the throat. If a local anesthetic is used for an adult tonsillectomy, the patient is placed in a sitting position.

c. The patient's head is covered with sterile towels and he is draped with a sheet as for nasal surgery.

d. For surgical procedures other than an adult tonsillectomy, a general anesthetic may be used. A local anesthetic is given to the adult for tonsil surgery unless that patient is allergic to the drug. To administer the local anesthetic, special tonsil needles are used. They are longer than the normal needles used for local infiltration and have a ridge which prevents their being inserted too deeply.

1-35. LARYNGOSCOPY

a. **General.** This procedure is a mode of direct visual examination of the interior of the larynx by means of an electric-lighted speculum known as a laryngoscope, in

order to obtain a specimen of tissue or secretions for pathological examination or to instill a drug. Both psychological and drug preparation are needed in order to have the patient relaxed. An oral sedative is given the night before and again about an hour before the examination.

b. **Setup.** Check the surgeon's card for the exact equipment required. It will also be necessary to find out the type of anesthetic needed. Very small infants will probably not need an anesthetic; children and adults who cannot relax are given a general anesthetic; adults who are well prepared do very well with the application of a topical anesthetic of lidocaine (Xylocaine[®]), tetracaine (Pontocaine[®]) or cocaine.

c. **Preparation of the Patient.** The patient is placed in a supine position, and an assistant holds the patient's head in the proper position for good visualization of the vocal cords.

d. **Operative Procedure.**

(1) The spatula end of the laryngoscope is introduced into the right side of the patient's mouth and directed toward the midline; then the dorsum of the tongue is elevated, exposing the epiglottis.

(2) The patient's head is first tipped backward and then elevated and lifted upward as the laryngoscope is advanced into the larynx.

(3) The larynx is examined, a biopsy is taken, secretions are aspirated, and bleeding controlled.

(4) The patient's face is cleansed. The patient is reassured and taken to his room or the recovery room.

1-36. TONSILLECTOMY AND ADENOIDECTOMY

a. **General.** Tonsils and adenoids that are hypertrophied or chronically infected are removed, which is called a tonsillectomy and adenoidectomy (T&A). Acute bacterial infections can attack a ring of lymphoid tissue encompassing the tonsil and adenoid tissue. Pain, malaise, anorexia, and increased temperature are typical symptoms.

b. **Preparation of the Operating Room.**

(1) The instruments in the setup include those needed for either sharp or blunt dissection, according to the method preferred by the surgeon.

(2) The number of tonsil sponges, with cords attached for applying pressure to the tonsil fossa, is included.

(3) The lighting of the room is provided for in accordance with the desire of the surgeon. The circulator is to carefully check all details of lighting.

(4) Tonsil snare wires must be prepared correctly. The loop in the snare wire must be large enough to pass over the handle of the tenaculum, but it must not be so large that its size prevents cutting through the pedicle of the tonsil. The scrub is to prepare the snares in accordance with local policy.

(5) The mouth gag used must be of a correct size (not too large) to avoid inflicting injury to the patient's gums and lips and to avoid the danger of dislodging or breaking any teeth.

(6) Special straight or curved needles with a security stop are used for the injection of the local anesthetic agent.

(7) Sponges are normally handed on a curved hemostat.

(8) Suction cautery is used for control of bleeding.

c. Preparation of the Patient.

(1) If a general anesthetic is to be administered, the patient is anesthetized first, then placed in a slight Trendelenburg position. The neck is hyperextended by placing a roll under the shoulders. If a local anesthetic is to be administered, the patient is placed in a sitting position.

(2) The patient's face may be cleaned with a germicide. The patient is draped as follows:

(a) An opened sheet and two opened towels are placed under the head of the patient.

(b) The uppermost towel is wrapped around the head and secured by forceps, and the free ends of the towel are tucked under the head.

(c) A second sheet is placed over the patient.

d. Operative Procedure.

(1) When a general anesthetic is used, the mouth is retracted open with a self-retaining retractor, the tongue depressed with a blade retractor, and an anesthesia tube placed in the corner of the mouth. An efficient suction apparatus is most important. The tonsil suction tube is introduced gently and passed along the floor of the mouth, over the base of the tongue, and into the pharynx. During the procedure, the suctioning ensures adequate exposure of the operative site and prevents blood reaching the lungs.

(2) The tonsil is grasped with a pair of tonsil-grasping forceps and the mucous membrane of the anterior pillar incised with a knife; the tonsil lobe is freed from its attachments to the pillars with a tonsil dissector, curved scissors, and gauze sponges on a holder. The tonsil is withdrawn with forceps.

(3) The posterior pillar is cut with scissors, and the tonsil is removed with a snare. In some cases, the LaForce or Sluder tonsil guillotine clamp may be used.

(4) A tonsil sponge is placed in the fossa by a hemostat.

(5) Bleeding vessels are clamped with tonsil forceps, tied with slipknot ligatures of absorbable suture and the free ligature ends are cut.

(6) The adenoids are removed with an adenotome or curette. Bleeding is controlled by pressure with sponges.

(7) The fossa is carefully inspected, and any bleeding vessels are clamped and tied. Retractors are removed, the face of the patient is cleaned, and his head is turned to one side. The patient is kept in the semirecumbent (Fowler) position or on his side horizontally, to avoid aspiration of blood and venous engorgement.

e. **Handling of Specimens.** Tissue excised is processed for examination by the laboratory.

f. **Suturing Types Usually Used.**

(1) Absorbable suture of size specified by the surgeon--used for free ligatures.

(2) Absorbable suture, of size specified by the surgeon, affixed on tonsil needle--used for suture-ligature.

1-37. SURGERY OF THE ORAL CAVITY

a. **General.** This procedure consists of the excision of benign or malignant lesions of the tongue, floor of the mouth, alveolar ridge, buccal mucosa, or tonsillar area. Benign or small malignant tumors of the oral cavity may be excised without neck dissection. In the presence of tongue cancer without evidence of metastasis, a "prophylactic" neck dissection may be performed in an effort to control a cancerous growth in the upper jugular chain of the neck. When treating a typical carcinoma of the floor of the mouth with involvement of the mandible, a portion of the tongue and the mandible are removed. When there is a lesion of the tonsil or an extensive lesion at the base of the tongue with pharyngeal wall involvement, a resection of the ascending ramus of the mandible is necessary, and portions of the base of the tongue, pharyngeal wall, and the soft palate are removed to secure an adequate margin of normal tissue about the lesion.

b. **Patient Preparation.** The patient is placed in dorsal recumbent position with shoulders elevated. Generally, endotracheal anesthesia is used, and a pharyngeal pack of moist gauze is inserted in the mouth.

c. **Operative Procedure.** Although the case may be scheduled as a local excision, frequently lesions of the oral cavity require more extensive excision than planned preoperatively. The setup should be designed to include the instruments for a neck dissection, or to have them available. In most tumors of the oral cavity, a tracheostomy is performed to assure an airway postoperatively.

1-38. ELECTIVE TRACHEOSTOMY

a. **General.** This procedure involves opening the trachea and inserting a cannula through a midline incision in the neck, below the cricoid cartilage. It is used as an emergency procedure to treat upper respiratory tract obstruction and as a prophylactic measure in the presence of chronic lung disease in which an obstruction could occur. A prophylactic tracheostomy is performed at the time of surgery, thus providing for easy and frequent aspiration of the tracheobronchial tree and diminishing the dead space that exists from the opening of the mouth down to the supraclavicular region. The creation of a new clearance (tracheostomy) nearer to the functional areas in the lung provides for greater volume of air for the patient with a partly destroyed lung. Anesthesia may be maintained via a prophylactic tracheostomy.

b. **Preparation of the Operating Room.** The standard instruments and other items needed are kept sterile in a pack, ready for immediate use. In addition, the circulator is to have a cardiac arrest tray immediately available.

c. **Preparation of the Patient.** The patient is placed in a dorsal recumbent position, with the shoulders raised by a folded sheet to hyperextend the neck and head. The neck is cleansed and sterile drapes applied as for operations of the thyroid.

d. Operative Procedure.

(1) A vertical or transverse incision may be used. A vertical incision is made in the midline from approximately the cricoid cartilage to the suprasternal notch. When a transverse incision is made, it extends approximately one fingerbreadth above the suprasternal notch parallel to it and from the anterior border of one sternocleidomastoid muscle to the opposite side. Soft tissues and muscle are divided, and the isthmus of the thyroid gland that joins both lobes of the gland in the midline over the trachea is retracted in an upward direction with Cushing retractors, thus resulting in exposure of the underlying tracheal rings, usually the third and fourth. In some cases, two curved clamps may be inserted through this incision across the isthmus and the isthmus transected. The transected ends of the isthmus are secured with chromic gut sutures.

(2) With a knife and #15 blade, a vertical incision is made in the trachea directly across the two tracheal rings. The cut ends of the cricoid cartilage are retracted with a hook.

(3) The previously prepared tracheostomy tube (see figure 1-12) is inserted into the trachea, the obturator is quickly removed, and the trachea is suctioned with a catheter.

(4) The wound edges are lightly approximated with silk sutures or the wound edges are allowed to fall together around the tube. One or two skin sutures are inserted above the tube. The lower angle of the wound may be left open for drainage.

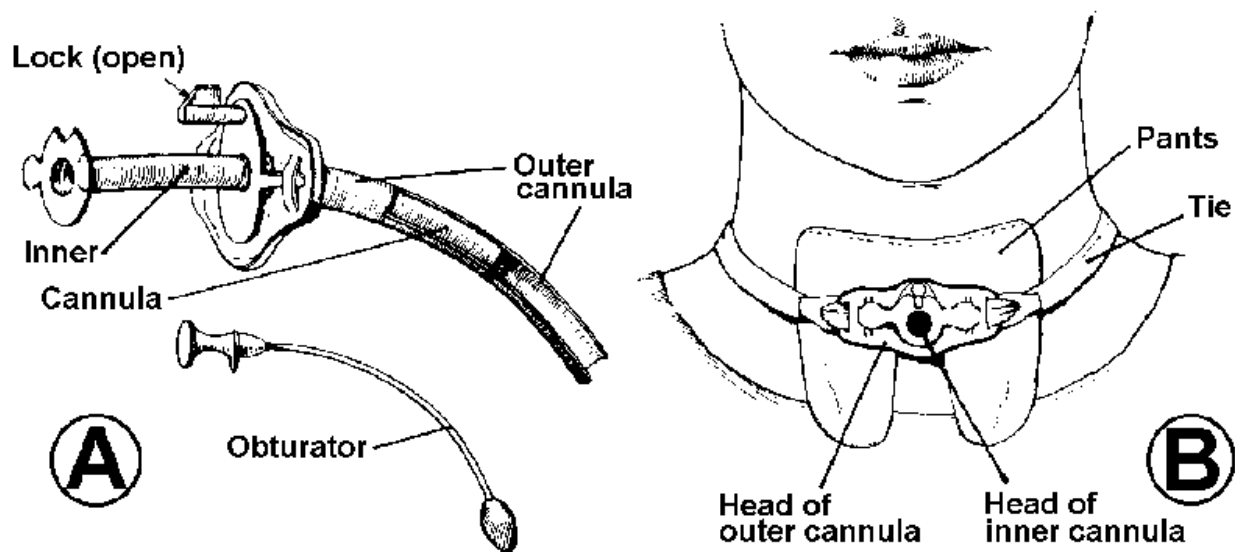


Figure 1-12. Metal tracheostomy tube. **A**-Parts of a metaltracheostomy tube. **B**-Tracheostomy ties and gauze pants in place.

(5) The tracheostomy tube is held in place with tapes tied with a square knot behind the neck. The inner tube is then inserted. A gauze dressing split around the tube is applied to the wound. Assembler

1-39. EXCISION OF THE SUBMAXILLARY GLAND

a. **General.** This operation involves the removal of the gland and tumor through an incision made in the neck, just beneath the chin. It is performed to remove mixed tumors and multiple calculi associated with extensive chronic inflammation.

b. **Preparation of the Patient.** The patient is placed on the table in a dorsal recumbent position, with the affected side uppermost, and prepared as for neck surgery.

c. Operative Procedure.

(1) A small skin incision is made below and parallel to the mandible, extending forward to beneath the chin. The platysma is incised with scissors; the skin flaps and undersurface of the platysma and cervical fascia covering the gland are undermined, using fine hooks, tissue forceps, and Metzenbaum scissors.

(2) The mandibular branch of the facial nerve is retracted away with a small loop retractor.

(3) The submaxillary gland is elevated from the mylohyoid muscle. The edge of the muscle is retracted to expose the lingual veins and nerve and the hypoglossal nerve.

(4) The gland is freed by blunt dissection, and the submaxillary (Wharton's) duct is clamped, ligated, and divided.

(5) The external maxillary artery is clamped, ligated, and divided. The submaxillary gland is removed.

(6) The wound is closed with interrupted fine silk or chromic gut sutures. The skin edges are approximated with nylon sutures. A Penrose drain is inserted in the submaxillary bed and secured to the skin. Dressings are applied.

1-40. PAROTIDECTOMY

a. **General.** This operation involves the removal of a tumor and gland through a curved incision in the upper neck and behind the lobe of the ear, or through a Y-type incision in both sides of the ear and below the angle of the mandible. The majority of benign tumors of the salivary glands occur in the parotid gland. These benign tumors are of the same types as are those found in soft tissues in other parts of the body. The closeness of the parotid gland to the facial nerve makes it difficult to remove the entire tumor. Parotidectomy is indicated for removal of all benign and some malignant tumors, for inflammatory lesions, for vascular anomalies, and for metastatic cancer involving lymph nodes overlying the gland. When malignant tumors are found to involve adjacent structures, the operation may have to be extended to become a more radical procedure.

b. **Preparation of the Patient.** The patient is placed on the operating table in a dorsal recumbent position with the entire affected side of the face uppermost. The entire side of the face, the mouth, the outer canthus of the eye, and the forehead are prepared and left exposed.

c. Operative Procedure.

(1) The incision may extend from the posterior angle of the zygoma downward in front of the tragus of the ear and behind the lobule of the ear backward

over the mastoid process, then downward and forward on the neck parallel to and below the body of the mandible. (A chin incision may be used.) Bleeding vessels are controlled by hemostats and fine ligatures.

(2) Using fine-toothed tissue forceps and scissors, the skin flaps are elevated as described for thyroidectomy. The skin wound edges are retracted away by means of silk sutures fastened to the clamps.

(3) The upper portion of the sternocleidomastoid muscle is exposed and retracted, the auricular nerve is identified, and the lower part of the parotid gland is elevated, using curved hemostats.

(4) The superficial temporal artery and vein and external jugular vein are identified by means of blunt dissection.

(5) The parotid tissue is dissected from the cartilage of the ear and the tympanic plate of the temporal bone. The temporal, zygomatic, mandibular, and cervical branches of the facial nerve are identified and preserved.

(6) The superficial portion of the parotid gland containing the tumor is removed. In some cases, the entire superficial portion is removed, followed by ligation and division of the parotid duct.

(7) When the deep portion of the parotid gland must be removed, the facial nerve is retracted upward and outward by nerve hooks; then the parotid tissue is removed from beneath the nerve. Kocher retractors are used to retract the mandible. The external carotid artery is identified. In many cases, the internal maxillary and superficial temporal arteries are clamped, ligated, and divided.

(8) The wound is closed in layers with fine silk sutures. A small Penrose drain is inserted, and a pressure dressing is applied.

1-41. LARYNGOFISSURE

a. **General.** This operation involves the opening of the larynx for exploratory, excisional, or reconstructive procedures. It is performed whenever access to the intrinsic larynx is necessary. The thyroid cartilages are split in the midline, and the true vocal cords and false vocal cords are incised at the midline anteriorly.

b. **Patient Preparation.** The patient is placed on the table in a dorsal recumbent position. The operative site is prepared and the patient draped with sterile sheets, as for thyroidectomy.

c. Operative Procedure.

(1) A tracheostomy is performed, and an endotracheal tube is inserted. A general anesthetic is administered, or the surgeon may elect to do the procedure with local anesthesia.

(2) A transverse incision is made through the skin and first layer of the cervical fascia and platysma muscles, approximately 2 cm above the sternoclavicular junction or in the normal skin crease by means of a knife handle #3 with a blade #10. The upper skin flap is undermined to the level of the cricoid cartilage; then the lower flap is undermined to the sternoclavicular joint.

(3) Bleeding vessels are clamped with mosquito hemostats and ligated. The strap muscles are elevated and incised in the midline.

(4) The thyroid cartilages are cut with a Stryker saw, and the true vocal cords are visualized through an incision into the cricothyroid membrane. The true vocal cords are divided in the midline (anterior commissure), and the interior of the larynx is exposed.

(5) The tracheostomy tube must be left in place postoperatively to ensure an airway.

1-42. PARTIAL LARYNGECTOMY

a. **General.** This operation involves the removal of a portion of the larynx. It is done to remove superficial neoplasms that are confined to one vocal cord or to remove a tumor extending up into the ventricle on the anterior commissure or a short distance below the cord. Cancers confined to the intrinsic larynx are generally of a low grade of malignancy and tend to remain localized for long periods.

b. **Preparation of the Patient.** The patient is placed on the table in a dorsal recumbent position. The operative site is prepared and the patient draped with sterile sheets, as described for thyroidectomy.

c. Operative Procedure.

(1) A tracheostomy is performed as previously described and an endotracheal tube is inserted.

(2) A vertical incision or a thyroid incision with elevation of a flap may be employed.

(3) The sternothyroid muscles are separated in the midline and retracted by means of loop retractors.

(4) The fascial covering over the thyroid cartilage is incised with a knife, and the perichondrium is elevated from the cartilage on the side of the tumor with a Freer periosteal elevator.

(5) The thyroid cartilage is divided longitudinally in midline by means of a Stryker power saw.

(6) The cartilages are retracted with loop retractors. The cricothyroid membrane is incised with a knife. A blunt-nosed laryngeal scissors is introduced between the vocal cords to divide the mucosa of the anterior wall of the glottis.

(7) The divided cartilages are retracted with Kocher retractors to expose the interior of the larynx. A small pack of moist gauze may be placed in the trachea to prevent aspiration of blood or mucous. A 10 percent solution of cocaine may be applied to the larynx to prevent laryngeal muscular spasm. The extent of the intrinsic laryngeal tumor is determined.

(8) With a small periosteal elevator, the mucosa on the involved side of the larynx is freed; the false cord and mucosal layer of the region are lifted by means of a periosteal elevator and hooks. The involved cord is excised, using straight scissors.

(9) In some cases, the thyroid cartilage may be removed with a knife and straight scissors. Bleeding is controlled with hemostats and fine chromic gut ligatures and sutures.

(10) The gauze pack is removed from the trachea. The perichondrium is approximated with chromic gut #2-0 sutures. The strap muscles are approximated in the midline with chromic gut #2-0 sutures; then the platysma and the skin edges are approximated separately with fine silk sutures.

(11) A tracheal-laryngeal tube is left in place. It is removed at a later date when the airway is adequate. Dressings are applied to the wound and around the tube.

1-43. SUPRAGLOTTIC LARYNGECTOMY

This procedure is the excision of the laryngeal structures above the true vocal cords. It is indicated in cancer of the epiglottis and false vocal cords. It is designed to remove the cancer, yet preserve the phonatory, respiratory, and sphincteric functions of the larynx. A neck dissection is always performed.

1-44. TOTAL LARYNGECTOMY

a. **General.** This procedure involves the complete removal of the cartilaginous larynx, the hyoid bone, and the strap muscles-connected to the larynx and possible removal of the pre-epiglottic space with the lesion. The tumor may have produced

immobility of the vocal cords, or be in the extrinsic larynx and hypopharynx where there is greater danger of metastasis. The lymphatics are often removed.

b. Psychological Aspects. Laryng-ectomy presents many psychological problems. The loss of voice that follows this procedure is a most tragic event for the patient and his family. The patient may be taught to talk either by using esophageal voice or with an artificial larynx. Esophageal voice is produced by the air contained in the esophagus rather than by that in the trachea. Speech requires a sounding air column. With instruction and practice, the patient is able to control the swallowing of air into the esophagus and re-introduction of this air into the mouth-with phonation. The sounding air column is then transformed into speech by means of the lips, tongue, and teeth.

c. Patient Preparation.

(1) The patient is placed on the table in a dorsal recumbent position with his neck extended and shoulders raised by a rubberized block or folded sheet. The table is slanted downward to elevate the upper part of the body for the convenience of the surgeon.

(2) An endotracheal anesthetic is administered. An effective suction apparatus is most essential.

(3) The proposed operative site--including the anterior neck region, lateral surfaces of the neck down to the outer aspects of the shoulders, and the upper anterior chest region--is cleansed in the usual manner.

d. Operative Procedure.

(1) A tracheostomy may be performed to control the airway.

(2) A midline incision is made from the suprasternal notch to just above the hyoid bone. Skin flaps are undermined on each side. The sternothyroid, sternohyoid, and omohyoid muscles (strap muscles) on each side are divided by means of curved hemostats and a knife.

(3) The suprahyoid muscles are severed from the portion of the hyoid to be divided. The hyoid bone is divided at the junction of its middle and lateral thirds with bone-cutting forceps. Bleeding vessels are clamped and ligated.

(4) The superior laryngeal nerve and vessels are exposed and ligated on each side, using long curved fine hemostats and fine chromic gut or silk ligatures.

(5) The isthmus of the thyroid gland is divided between hemostats. Each portion of the thyroid gland-is dissected from the trachea, using fine dissection with Stevens and Metzenbaum scissors and fine tissue forceps. The superior pole of the

thyroid is retracted in a Greene retractor. The superior thyroid vessels are freed from the larynx by a sharp dissection.

(6) The larynx is rotated. The inferior pharyngeal constrictor muscle is severed from its attachment to the thyroid cartilage on each side.

(7) The endotracheal tube is removed. The trachea is transected just below the cricoid cartilage over a Kelly or Crile hemostat previously inserted between the trachea and esophagus. The upper resected portion of the trachea and the cricoid cartilage are held upward with Lahey forceps. A balloon-cuffed tube (endotracheal) or a Foley catheter is inserted in the distal trachea.

(8) The larynx is freed from the cervical esophagus and attachments by sharp and blunt dissection. A moist pack is placed around the endotracheal tube to help prevent leakage of blood into the trachea.

(9) The pharynx is entered. In most cancers of the intrinsic larynx, the pharynx is entered above the epiglottis. The mucosal membranous incision is extended along either side of the epiglottis; the remaining portion of the pharynx and cervical esophagus is dissected well away from the tumor by means of fine-toothed tissue forceps, Metzenbaum scissors, knife, suctioning, and fine hemostats. The specimen is removed en massa.

(10) A nasal feeding tube is inserted through one nares into the esophagus; closure of the hypopharyngeal and esophageal defect is begun, using continuous inverting fine sutures of chromic gut #3-0. The nasal tube is guided down past the pharyngeal suture line.

(11) The pharyngeal suture line is reinforced with interrupted sutures; the suprahyoid muscles are approximated to the cut edges of the inferior constrictor muscles.

(12) The diameter of the tracheal stoma is increased by means of a knife and heavy straight scissors. The two portions of the thyroid behind the tracheal opening are approximated with interrupted silk sutures, thereby obliterating dead space posterior to the upper portion of the trachea.

(13) A small Penrose drain or catheter is inserted through two separate stab wounds on each side of the neck just below the pharyngeal suture line. If a closed suction system is used, catheters connected to a suction apparatus are used.

(14) The edges of the deep cervical fascia and the platysma are closed separately with interrupted fine silk sutures. When a great amount of the fascia and platysma has been removed, the wound edges are approximated with silk sutures.

(15) A laryngectomy tube is inserted into the tracheal stoma; a pressure dressing is applied to the wound and neck.

1-45. RADICAL NECK DISSECTION

a. **General.** This operation involves the removal of a tumor, surrounding structures, and lymph nodes en massa, through a Y-shaped or trifurcate incision in the affected side of the neck. It is done to remove the tumor and metastatic cervical nodes present in malignant lesions and all nonvital structures of the neck. Metastasis occurs through the lymphatic channels via the bloodstream. Disease of the oral cavity, lips, and thyroid gland may spread slowly to the neck. Radical neck surgery is done in the presence of cervical node metastasis from a cancer of the head and neck, which has a reasonable chance of being controlled. It may also be done in a slightly less radical form when there is cancer of the tongue and no firm evidence of metastasis.

b. Preparation of the Patient.

(1) The patient is placed on the table in a dorsal recumbent position, with the head in moderate extension and the entire affected side of the face and neck facing uppermost. During surgery, the face of the patient is turned away from the surgeon.

(2) The preoperative skin preparation is extensive. The patient is draped with sterile towels and sheets, leaving a wide operative field. Endotracheal anesthesia is used. The anesthetic is administered before the patient is positioned for surgery. During the operation, the anesthesiologist works behind the sterile barrier, away from the surgical team.

c. Operative Procedure.

(1) One of several types of incisions may be used, including the Y-shaped, H-shaped, or trifurcate incision.

(2) The upper curved incision is made through the skin and platysma, using a knife, tissue forceps, and fine hemostats and ligatures for bleeding vessels. The upper flap is retracted; then the vertical portion of the incision is made and the skin flaps retracted anteriorly and posteriorly with retractors. The anterior margin of the trapezius muscle is exposed by means of curved scissors. The flaps are retracted to expose the entire lateral aspect of the neck. Branches of the jugular veins are clamped, ligated, and divided.

(3) The sternal and clavicular attachments of the sternocleidomastoid muscle are clamped with curved Rochester-Mayo clamps and then divided with a knife. The superficial layer of deep fascia is then incised. The omohyoid muscle is severed between clamps just above its scapular attachment.

(4) The internal jugular vein is isolated by blunt dissection and then doubly clamped, ligated with medium silk, and divided with Metzenbaum scissors. A transfixion suture is placed on the lower end of the vein.

(5) The common carotid artery and vagus nerve are identified. The fatty areolar tissue and fascia are dissected away, using Metzenbaum scissors and fine tissue forceps. Branches of the thyrocervical artery are clamped, divided, and ligated.

(6) The tissue and fascia of the posterior triangle are dissected, beginning at the anterior margin of the trapezius muscle, continuing near the brachial plexus and the levator scapulae and the scalene muscles. During the dissection, branches of the cervical and suprascapular arteries are clamped, ligated, and divided.

(7) The anterior portion of the block dissection is completed. The omohyoid muscle is severed at its attachment to the hyoid bone. Bleeding is controlled. All hemostats are removed, and the operative site is covered with warm, moist laparotomy packs.

(8) The sternocleidomastoid muscle is severed and retracted. The submental space is dissected free of fatty areolar tissue and lymph nodes from above downward.

(9) The deep fascia on the lower free edge of the mandible is incised; the facial vessels are divided and ligated.

(10) The submaxillary triangle is entered. The submaxillary duct is divided and ligated. The glands with surrounding fatty areolar tissue and lymph nodes are dissected toward the digastric muscle. The facial branch of the external carotid artery is divided. Portions of the digastric and stylohyoid muscles are severed from their attachments to the hyoid bone and on the mastoid. The upper end of the internal jugular vein is elevated and divided. The surgical specimen is removed.

(11) The entire field is examined for bleeding and then irrigated with warm saline solution. Penrose drains are placed in the wound and brought out through a stab wound, and #12 Fr catheters may be used.

(12) The flaps are then approximated with interrupted fine silk sutures. A bulky pressure dressing is applied to the neck. Gauze dressings are applied to the wound edges and covered with sterile fluffed gauze to provide even pressure. A wide gauze roller bandage is wrapped snugly around the neck and in some cases encircles the head. The dressing may then be covered with elastic bandage that is wrapped around the neck and anchored to the chest wall.

Continue with Exercises

EXERCISES, LESSON 1

INSTRUCTIONS: The following exercises are to be answered by marking the lettered response that best answers the question or best completes the incomplete statement or by writing the correct word or phrase in the space provided.

After you have completed all the exercises turn to "Solutions to Exercises" at the end of the lesson and check your answers.

1. In treating eye infections, _____ should not be used.
 - a. Stains.
 - b. Miotics.
 - c. Antibiotics.
 - d. Corticosteroids.

2. A chalazion is a small:
 - a. Plastic operation on the eyelid.
 - b. Benign tumor of the eyelid.
 - c. Silk suture.
 - d. Sty.

3. A benign growth of conjunctival tissue over the cornea is called a:
 - a. Ptosis.
 - b. Hordeolum.
 - c. Pterygium.
 - d. Tarsorrhaphy.

4. If an eye is pulled inward by muscular imbalance, the condition is called:
 - a. Tarsorrhaphy.
 - b. Chalazion.
 - c. Esotropia.
 - d. Ptosis.

5. A hordeolum is a(n) _____.

6. The operation in which an extraocular muscle is freed from its attachment point and reattached closer to the cornea is called:
 - a. Advancement.
 - b. Recession.
 - c. Tenotomy.
 - d. Tucking.

7. The "exciting eye" is referred to as the eye that is:
 - a. Hard to focus.
 - b. Twitching.
 - c. Injured.
 - d. Bright.

8. Exenteration of the orbit is usually performed for treatment for:
 - a. Injury.
 - b. Myopia.
 - c. Diabetes.
 - d. Malignant tumor.

Special Instructions for Exercises 9 through 15. Indicate whether each of the following statements is true or false. Circle the "T" if the statement is true; circle "F" if it is false.

- T F 9. Miotic drugs cause the pupil of the eye to contract.
- T F 10. To distribute their effect, instill eye drops in various places of the eye.
- T F 11. When cleaning up after eye surgery, stack the instruments.
- T F 12. Medical treatment for cataracts is often adequate.
- T F 13. The pharynx is composed largely of muscle and fibrous tissue.
- T F 14. Laryngoscopy can be done on relaxed, well-prepared adults with a topical anesthetic.
- T F 15. Although tumors of the mouth may be scheduled as a local excision, they frequently become much more extensive during the procedure.
16. Which of the following items might be used to locate a foreign body in the eye?
- a. X-ray exposures.
 - b. Ultrasonic probes.
 - c. Metal-locating instruments.
 - d. All of the above.
17. In a cataract operation, the _____ is removed.
- a. Lateral recuts.
 - b. Choroid.
 - c. Retina.
 - d. Lens.

18. The middle ear contains air and:
- a. Three small bones.
 - b. Organ of Corti.
 - c. Labyrinth.
 - d. Fluid.
19. The ear is made up of the external ear, the inner ear, and the:
- a. Tympanic membrane.
 - b. Temporal bone.
 - c. Middle ear.
 - d. Labrinth.
20. Otological surgery involves the:
- a. Eye.
 - b. Ear.
 - c. Nose.
 - d. Throat.
21. What incision may be used for surgery of the mastoid process?
- a. Endaural.
 - b. Vertical.
 - c. Postaural.
 - d. Circumferential.

22. An incision through the tympanic membrane is called a:
- Mastoidectomy.
 - Tympanoplasty.
 - Myringotomy.
 - Chalazion.
23. Simple mastoidectomy has been made essentially obsolete by:
- Radical mastoidectomy.
 - Operating microscopes.
 - Tympanoplasty.
 - Antibiotics.
24. The columella is formed by part of the septal cartilage, the major alar cartilages, and the:
- Hyoid bone.
 - Soft palate.
 - Hard palate.
 - Anterior nasal spine.
25. The nasal cavity is separated from the lingual cavity by the hard and soft palates and from the cranial cavity by the _____ bone.
- Nasal.
 - Ethmoid.
 - Parietal.
 - Temporal.

26. Another name for the maxillary sinus is _____.
27. Nasal surgery on adults is normally done using _____ anesthetic.
- General.
 - Local.
28. Another name for a radical antrostomy is the _____ operation.
29. A sinus operation involving incision through the eyebrow would ordinarily involve the _____ sinus.
30. A fingerlike projection at the posterior border of the soft palate is called the _____
31. During the act of swallowing, the nasopharynx is:
- Open.
 - Closed.
32. The adenoids consist of an accumulation of _____ tissue.
- Lymphoid.
 - Salivary.
 - Muscular.
 - Connective.

33. The larynx has three functions. It serves as a passageway for air, a valve to close air passages during swallowing, and as a:
- Joint.
 - Voice box.
 - Lymph gland.
 - Vertebral structure.
34. The production of vocal sound in the larynx is by the vocal cords that are folds containing a blend of mucous membrane and _____ tissue.
- Fibrous.
 - Nervous.
 - Muscular.
 - Glandular.
35. When we speak, we use the breathing muscles, the vocal cords, and:
- The lips.
 - The tongue.
 - The soft palate.
 - All of the above.
36. Damage to or paralysis of the laryngeal nerves will cause an emergency in which a/an _____ will probably be necessary.
- Oxygen tent.
 - Tracheostomy.
 - Appendectomy.
 - Blood transfusion.

37. For adult tonsillectomies, _____ anesthesia is usually used.
- a. General.
 - b. Local.

Check Your Answers on Next Page

SOLUTIONS TO EXERCISES, LESSON 1

1. d (para 1-3a(2)(e))
2. b (para 1-9c)
3. c (para 1-9d)
4. c (para 1-11a)
5. sty (para 1-9e)
6. a (para 1-11e)
7. c (para 1-12a)
8. d (para 1-12c)
9. T (para 1-3a(2)(d))
10. F (para 1-3e(4)(a))
11. F (para 1-5d(1))
12. F (para 1-15a)
13. T (para 1-33b)
14. T (para 1-35b)
15. T (para 1-37c)
16. d (para 1-14a(1) and (2))
17. d (para 1-15a)
18. a (para 1-18c)
19. c (para 1-18)
20. b (para 1-20c(1))
21. c (para 1-22c)

22. c (para 1-23a)
23. d (para 1-25a)
24. d (para 1-28a(1))
25. b (para 1-28b(2))
26. Antrum of Highmore (para 1-28c(2))
27. b (para 1-29d)
28. Caldwell-Luc (para 1-31d)
29. Frontal (para 1-31e(2)(a))
30. Uvula (para 1-33a)
31. b (para 1-33b(2))
32. a (para 1-33c(1))
33. b (para 1-33d(1)(a))
34. a (para 1-33d(3)(b))
35. d (para 1-33d(4)(b))
36. b (para 1-33d(4)(d))
37. b (para 1-34d)

End of Lesson 1

LESSON ASSIGNMENT

LESSON 2

Procedures in Gynecological and Obstetrical Surgery.

TEXT ASSIGNMENT

Paragraphs 2-1 through 2-44.

LESSON OBJECTIVES

After completing this lesson, you should be able to:

- 2-1. Identify terms and their definitions that are related to obstetrical and gynecological surgery.
- 2-2. Identify the anatomy of the female reproductive system.
- 2-3. Identify patient preparation for obstetrical and gynecological surgery.
- 2-4. Identify procedures used for vaginal, abdominal gynecological, and obstetrical surgery.

SUGGESTION

After completing the assignment, complete the exercises at the end of this lesson. These exercises will help you to achieve the lesson objectives.

LESSON 2

PROCEDURES IN GYNECOLOGICAL AND OBSTETRICAL SURGERY

Section I. ANATOMY OF THE FEMALE REPRODUCTIVE SYSTEM

2-1. INTRODUCTION

a. A general understanding of the anatomy and physiology of the female pelvis, reproductive organs, and associated structures (such as the bony pelvis) is necessary for the operating room staff. Application of anatomy is extremely important in positioning the patient for surgery, in selecting the proper instruments and sutures for a specific type of operation, and in understanding the plan of surgery.

b. The female reproductive organs and their relationships are shown in figure 2-1. The adult female structures directly and indirectly associated with the process of reproduction include the bony pelvis, the associated ligaments and muscles, the soft tissues and contents of the pelvic cavity, and the external organs (vulva).

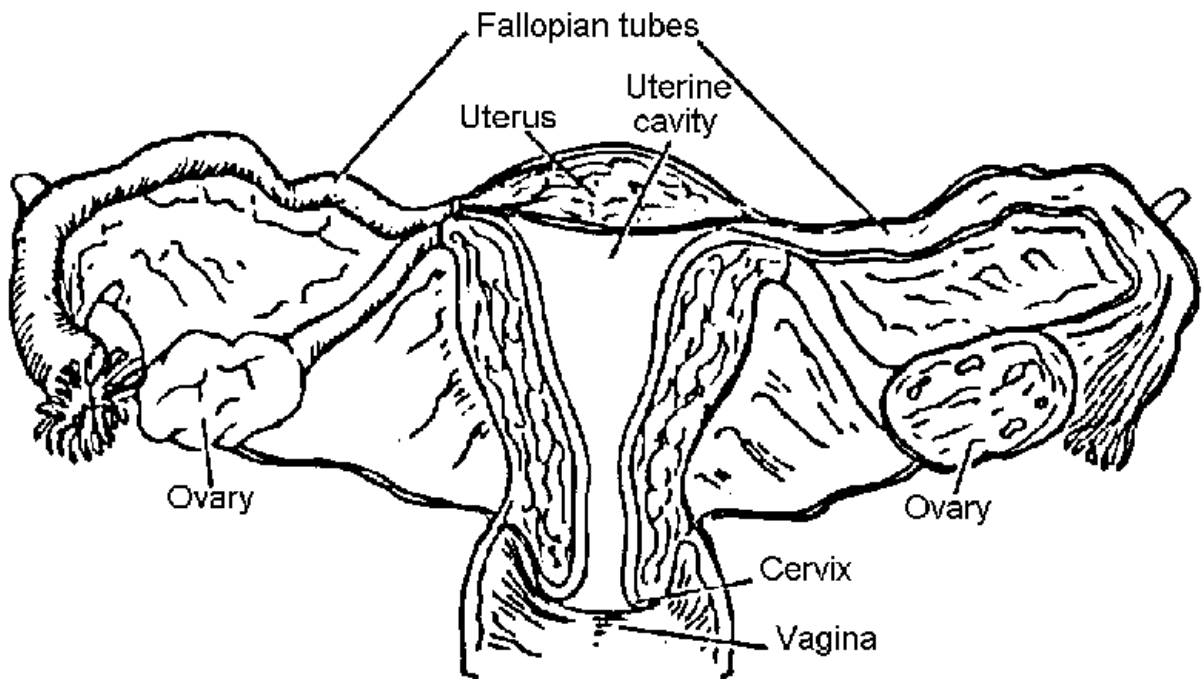


Figure 2-1. Female reproductive organs.

2-2. THE BONY PELVIS

a. The Latin word pelvis means basin. The pelvis is that part of the trunk which is surrounded by the bony pelvis. The bony pelvis (see figure 2-2) is made up of the ilium, pubis, ischium, sacrum, and coccyx. The so-called pelvic brim divides the

abdominal (false) portion from the true portion of the pelvis. The abdominal (false) pelvis is the part above the arcuate line. The true pelvis is the part below this line. It forms the passageway through which the infant passes during parturition.

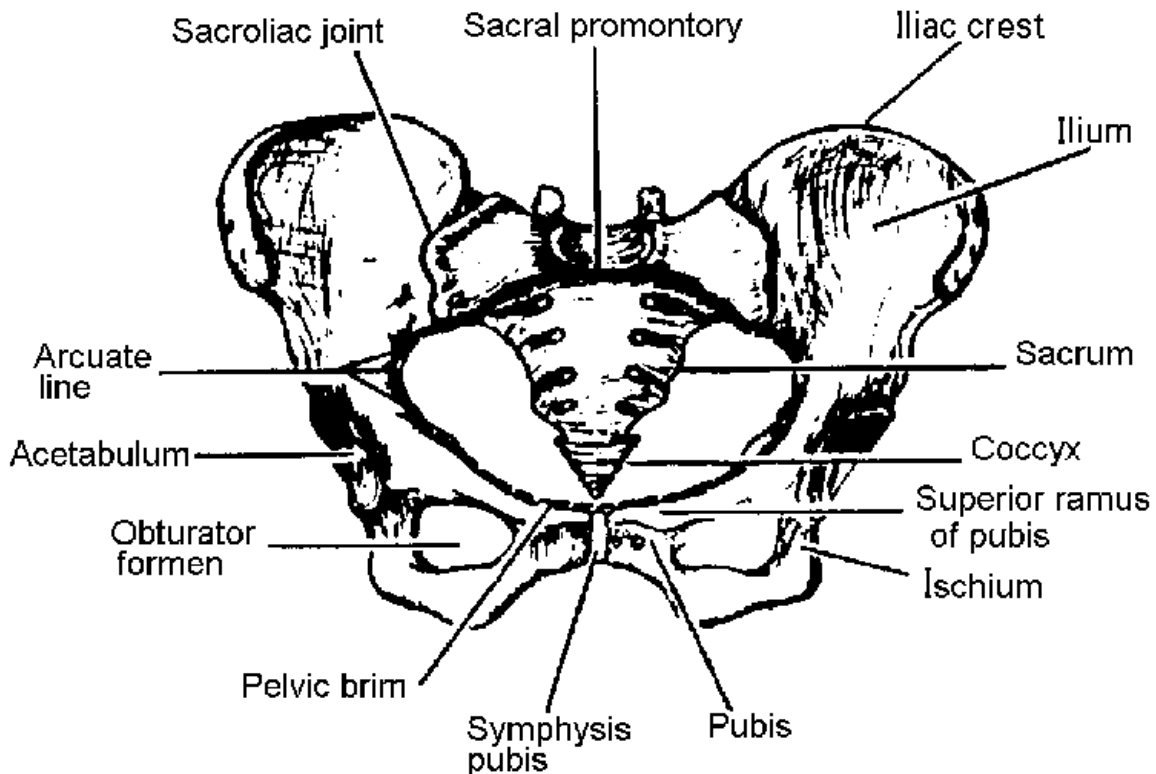


Figure 2-2. The pelvic girdle.

b. The true pelvis may be considered as having three parts: the inlet, cavity, and outlet. The muscles lining the pelvis facilitate movement of the thighs, give form to the pelvic cavity, and provide firm elastic lining to the bony pelvic framework. All organs located in the pelvis are covered by pelvic fascia. The fascia covering some muscles is dense and firm, whereas that covering other organs is thin and elastic. The nerves, blood vessels, and ureters passing through the anatomical structures are closely associated with the muscular and fascial structures.

c. The pelvic fascia may be divided into three general groups: parietal, diaphragmatic, and visceral. The parietal pelvic fascia covers the muscles of the true pelvic wall and the perineum. The diaphragmatic fascia covers both sides of the pelvic diaphragm, which is made up of the levator ani and coccygeal muscles. The visceral fascia is thin flexible fascia that covers the pelvic organs. The floor of the pelvis, known as the pelvic diaphragm, gives support to the abdominal pelvic viscera in this region. The pelvic diaphragm, consisting of the levator ani and coccygeal muscles with their respective fascial coverings, separates the pelvic cavity from the perineum. The basis of modern vaginal surgery is concerned with the function of the levator ani muscles and the provision of an effective lower outlet.

d. The levator ani muscles, varying in thickness and strength, may be divided into three parts: the iliococcygeal, the pubo-coccygeal, and the puborectal muscles. The fibers of the levator ani blend with muscle fibers of the rectum and vagina. The fibers (pubovaginal) of the pubococcygeal part of the levator ani muscles, lying directly below the urinary bladder, are involved in the control of micturition. The pubococcygeal fibers of the levator ani control and pull the coccyx forward and assist in the closure of the pelvic outlet. The fibers pull the rectum, vagina, and bladder neck upward toward the symphysis in an effort to close the pelvic outlet and are responsible for the flexure at the anorectal junction. Relaxation of the fibers during defecation permits a straightening at this junction. During parturition, the action of the levator ani directs the fetal head into the lower part of the passageway.

e. The uterus gains much of its support by its direct attachment to the vagina and by indirect attachments to nearby structures such as the rectum and pelvic diaphragm. The ligaments and muscles on each side of the uterus are the broad, round, cardinal (Mackenrodt), and uterosacral ligaments and the levator ani muscles.

2-3. THE UTERUS

The uterus, which occupies a central place in the pelvis, is a pear-shaped organ directed downward and backward. At the upper lateral points, the uterus receives the uterine tubes (Fallopian tubes). The fundus of the uterus is the upper rounded portion situated above the level of the tubal openings. The main portion of the uterus is called the body. Below, the body of the uterus joins the cervix, from which it is separated by a slightly constricted canal, called the isthmus. The cervix lies at the level of the ischial spines. The lumen of the body of the uterus communicates with the cervical canal at the internal orifice, called the internal os. The cervical canal ends at the vaginal opening of the cervix called the external os. This is a small oval aperture situated between two lips.

2-4. THE STRUCTURE OF THE UTERUS (FIGURE 2-3)

a. The Greek word for uterus is hystera. The uterus lies behind the bladder and in front of the rectum (see figure 2-3). The uterine body has three layers: (1) the outer peritoneal, or serous layer, which is a reflection of the pelvic peritoneum; (2) the myometrium, or muscular layer, which houses involuntary muscles, nerves, blood vessels, and lymphatics; and (3) the endometrium, or mucosal layer, which lines the cavity of the uterus.

b. The cervix consists of a supravaginal and a vaginal portion. The supravaginal portion is closely associated with the bladder and the ureters. The vaginal portion of the cervix projects downward and backward into the top of the vaginal vault.

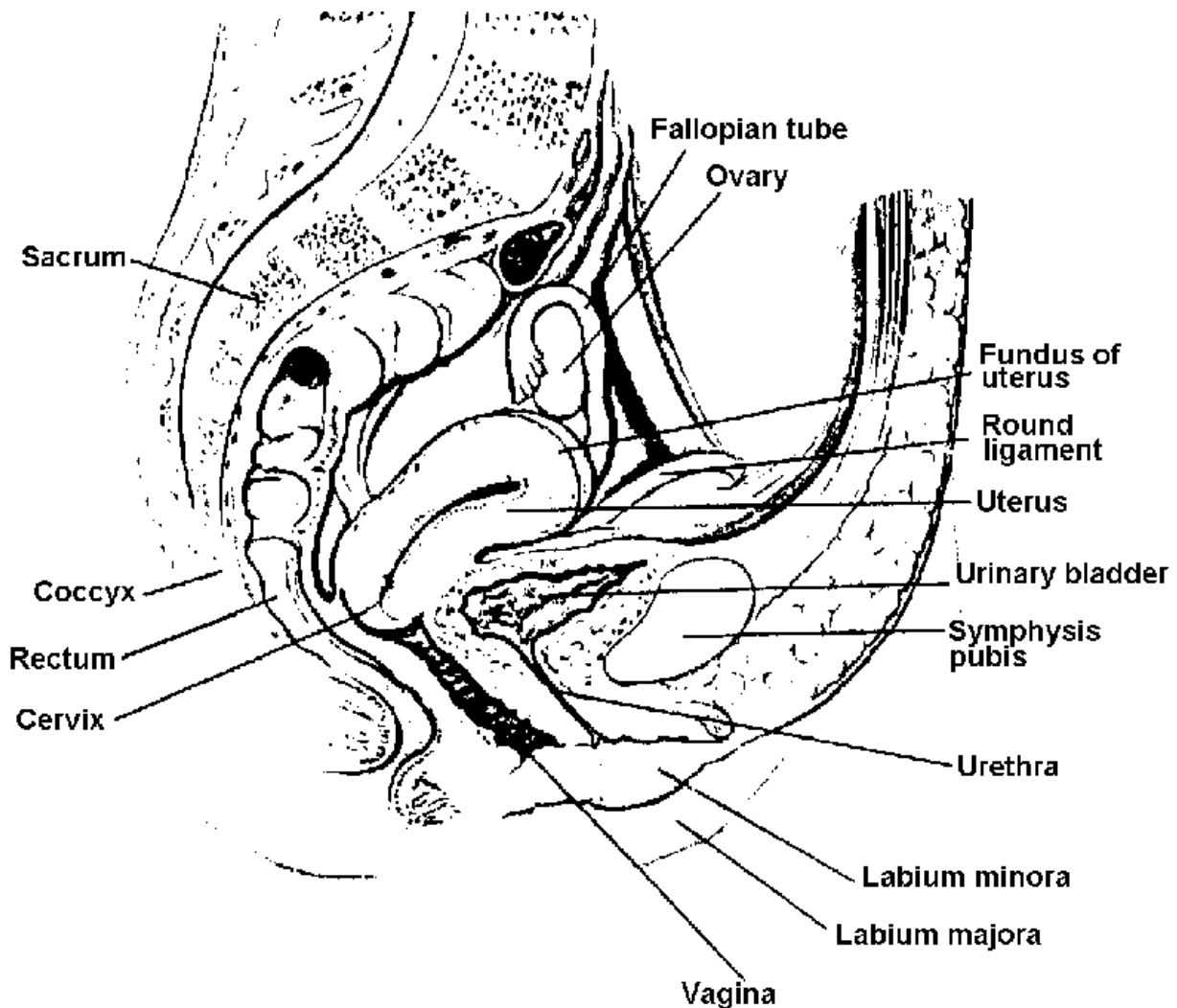


Figure 2-3. Pelvic region of female, median sagittal section.

2-5. UTERINE (FALLOPIAN) TUBES

a. The Greek word "salpinx," meaning trumpet or tube, is used in referring to the uterine tube. Bilateral tubes, each consisting of a musculomembranous channel about 4 to 5 inches long, form the canals through which the ova from either ovary are conveyed to the uterus. Each uterine tube leaves the upper portion of the uterus, passes outward toward the sides of the pelvis, and ends in fringed-like projections, called fimbriae. These are situated just below the ovaries. The fimbriae catch the ova, and the tubes convey the ova to the cavity of the uterus. This channel also transmits spermatozoa in the opposite direction. The tubes are covered on their outer surfaces by peritoneum. Each tube receives its blood supply from the branches of the uterine and ovarian arteries.

b. How the ova are transported from the ruptured follicle into the uterus is unknown. One theory is that the transfer is accomplished through vascular changes,

together with contraction of the smooth muscle fibers of the tube and that the peristaltic movements of the tube push the ova toward the uterus.

c. The right tube and ovary are in close relationship to the cecum and appendix, and the left tube and ovary are associated with the sigmoid flexure of the colon. Both are closely associated with the ureters.

2-6. THE OVARIES

a. Each ovary, situated at the side of the uterus, lies within a depression (ovarian fossa) on the lateral wall of the pelvic cavity on the posterior surface of the broad ligament. The ovary is attached to the posterior surface of the broad ligament by the mesovarium and is kept in place by the ovarian ligament. The ovary, a small, flattened, almond-shaped organ, is composed of an outer layer, known as the cortex, and an inner vascular layer, known as the medulla. The cortex contains ovarian (graafian) follicles in different stages of maturity. After ovulation, the corpus luteum is developed within the ovary by reorganization of the graafian follicles. The medulla, lying within the cortex, consists of connective tissue containing nerves, blood, and lymph vessels. The ovary is covered by epithelium, not by peritoneum.

b. The ovaries are homologous with the testes of the male. They produce ova after puberty and also function as endocrine glands, producing hormones. The estrogenic hormone is secreted by the ovarian follicle. It controls the development of the secondary sexual characteristics and initiates growth of the lining of the uterus during the menstrual cycle. The progesterone hormone, which is secreted by the corpus luteum, is essential for the implantation of the fertilized ovum and for the development of the embryo.

2-7. THE LIGAMENTS OF THE UTERUS

a. **Broad Ligaments.** From each side of the uterus, the pelvic peritoneum extends laterally, downward, and backward. A double fold of pelvic peritoneum forms the layers of the broad ligament, enclosing the uterus. These layers separate to cover the floor and sides of the pelvis. The uterine tube is situated within the free upper border of broad ligament. The part of the broad ligament lying immediately below the uterine tube is termed the mesosalpinx. The ovary lies behind the broad ligament.

b. **Round Ligaments.** These fibromuscular bands are attached to the uterus. Each round ligament passes forward and laterally between the layers of the broad ligament to enter the deep inguinal ring.

c. **Transverse Cervical Ligaments.** These cardinal ligaments are composed of connective tissue masses with smooth muscle fibers that are strong support for the uterus in the pelvis.

d. **Uterosacral Ligaments.** These are a posterior continuation of the peritoneal tissue, which forms the cardinal ligaments. The ligaments pass posteriorly to the sacrum on either side of the rectum.

2-8. THE VAGINA

This is a tubelike organ for copulation and the excretory duct for the products of menstruation. It is directed downward and forward, situated in front of the rectum and behind the bladder. The upper part of the vagina lies above the pelvic floor and is surrounded by visceral pelvic fascia. The lower half is surrounded by the levator ani muscles.

2-9. THE FORNICES

a. The projection of the cervix into the vaginal vault divides the vault into four regions which are called fornices (anterior and posterior, right and left lateral).

b. The posterior fornix is in close contact with the peritoneum of the pouch of Douglas. The rectovaginal septum lies between the vagina and rectum. The dense connective tissue separating the anterior wall of the vagina from the distal urethra is called the urethrovaginal septum.

2-10. FEMALE EXTERNAL GENITAL ORGANS (VULVA)

a. The external organs are referred to collectively as the vulva. The vulva is comprised of the paired labia majora, the paired labia minora, the clitoris and the vestibule. The vulva occupies the central portion of the perineal region. The mons veneris, urethra, and Skene's glands are in close proximity to the vulva.

b. The mons pubis (veneris) is a rounded elevation of tissue covered by skin and, after puberty, by hair. It is situated in front of the symphysis pubis.

c. The labia majora are two folds of skin that extend downward and backward. They unite below and behind to form the posterior commissure and in front to form the anterior commissure. They form the lateral boundaries of the vulva. A Bartholin gland is situated in each of the labium majus.

d. The labia minora are the two delicate folds of skin that lie within the labia majors. Anteriorly each labium minus splits into lateral and medial parts. The lateral part forms the prepuce of clitoris, and the medial part forms the frenulum. The posterior folds of the labia are united by a delicate fold extending between them. This forms the fourchette.

e. The clitoris is the homologue of the penis in the male. It hangs free and terminates in a rounded glans (small sensitive vascular body). Unlike the penis, the clitoris is not traversed by the urethra.

f. The vestibule is a smooth area surrounded by the labia minora, with the clitoris at its apex and the fourchette at its base. It contains openings for the urethra and the vagina.

g. The urethra, which is about 4 cm long, is in close relationship with the anterior vaginal wall and connects the bladder with the outside, acting as an excretory duct. At each side of the external urethral orifice (meatus) lie two small ducts, termed the paraurethral ducts, which drain small urethral glands (Skene's).

h. The vaginal opening lies behind the urethral orifice, and in the virgin it is almost closed by the hymen, a fold of vaginal mucosa.

i. The vestibular glands (Bartholin) lie one at each side of the lower end of the vagina. They are homologous of the bulbourethral glands of the male. The narrow gland duct opens into the vaginal orifice on the inner aspects of the labium minus.

2-11. VASCULAR, NERVE, AND LYMPHATIC SUPPLY

a. The blood supply of the female pelvis is derived from the internal iliac branches of the common iliac arteries and is supplemented by the ovarian and median sacral arteries, which are branches of the aorta.

b. The nerve supply of the female pelvis comes from the autonomic nerves, which enter the pelvis in the superior hypogastric plexus (presacral nerve).

c. The lymphatics of the female pelvis either follow the course of the vessels to the iliac and preaortic nodes or empty into the inguinal glands.

Section II. VAGINAL SURGERY

2-12. PATIENT PREPARATION

a. Surgery on the structures of the reproductive system in the female may be done either for diagnostic purposes or as a form of therapy in the treatment of a pelvic condition such as uterine bleeding or suspected cancer. Surgery is also done to remove tumors or repair structures.

b. For vaginal and perineal surgery, the lithotomy position is generally used. For abdominal surgery, the patient is placed in a modified or extreme Trendelenburg position. Care should be taken to prevent the patient from nerve injury and provide for circulatory and respiratory functioning.

c. Skin preparation and draping procedures are routine. A sterile lithotomy pack is needed for vaginal surgery, a laparotomy pack for abdominal surgery.

d. Because pelvic and vaginal procedures involve manipulation of the ureters, bladder, and urethra, indwelling urinary drainage systems are frequently established during surgery. Either the urethral Foley catheter or the suprapubic Silastic cannula directly into the bladder may be used, depending on the surgeon's preference and the type of surgery.

2-13. SIMPLE VULVECTOMY

a. **General.** This operation involves the removal of the labia majora, the labia minora, and possibly the clitoris and perianal area, with a Z-plasty closure. Simple vulvectomy may be done to treat leukoplakia vulvae because of its known association with carcinoma of the vulva, an intractable pruritus in older women, or other types of skin lesions such as kraurosis and vitiligo. It may also be used for carcinoma in situ of the vulva, Bowen's disease of the vulva, and Padgett's disease of the vulva.

b. **Patient Preparation.** The patient is anesthetized and placed in the lithotomy position. The operative site is cleansed, using the standard sterile vaginal set, and the patient is draped for lithotomy.

c. Operative Procedure.

(1) The affected skin is incised, usually starting anteriorly above the clitoris. The incision is continued laterally to the labia majora, to the midline of the perineum, and around the anus if it is involved. A knife, holding forceps, gauze sponges on holders, tissue forceps, and Allis forceps are needed. Bleeding vessels are clamped. Bleeding is controlled by the electrosurgical unit or plain or chromic gut ligatures.

(2) Periurethral and perivaginal incisions are made. Bleeding of this vascular area is controlled by means of Kelly or Crile hemostats, ligatures, and sponges on holders. Allis-Adair forceps are used for holding diseased tissues.

(3) All skin and subcutaneous tissues are undermined and mobilized, using curved dissecting tissue forceps, scissors, Allis forceps, and sponges on holders.

(4) The wound is closed, usually by simple bilateral Z-plasty closure with chromic gut number2-0 or number3-0. In some cases, an excision of the skin is made around the anus to accomplish a slide skin flap.

(5) Drains or continuous suction sometimes are placed in the dependent areas, an indwelling system or urinary drainage is established, and gauze packing is placed in the vagina. Petrolatum gauze and dressings are applied and held in place with plastic tape and a binder.

2-14. RADICAL VULVECTOMY AND GROIN LYMPHADENECTOMY

a. **General.** This operation involves abdominal and perineal dissection, which may be performed as a one-stage or two-stage operation. A mass dissection is done on the following structures: a large segment of skin from the abdomen and groins, the labia majora, labia minora, clitoris, mons pubis, and terminal portions of the urethra, vagina, and other vulvular organs, as well as the superficial and/or deep inguinal nodes, portions of the round ligaments, portions of the saphenous veins, and the lesion itself. It also involves reconstruction of the vaginal walls and pelvic floor and closure of the abdominal wounds. At a later date, placement of full-thickness pinch grafts may be done if the denuded area of the vulva appears too large for normal granulation.

b. **Preparation of the Patient.** The patient lies supine and may be placed in the Trendelenburg and lithotomy positions, as required for the various stages. The skin preparation includes both the abdomen and vulva, and the skin of the thighs is usually prepared down to the knees. As in other radical surgery, the nursing team should be prepared to measure blood loss and anticipate procedures to combat shock.

c. **Operative Procedure** (see figure 2-4).

(1) Lymphadenectomy portion of the surgery.

(a) The first skin incision is made on the side opposite the primary lesion. The end of the incised skin is grasped with Allis forceps. The incision is carried down to the aponeuroses of the external oblique muscle.

(b) The fascia over the inguinal ligament and the fascia lata of the upper thigh are exposed, separated, and freed, using retractors, knife, scissors, hemostats, and sponges.

(c) Bleeding vessels are clamped and ligated, including the superficial iliac artery and vein, the epigastric artery and vein, and the superficial external pudendal artery and vein using Crile hemostats and ligatures or chromic gut or silk number 0 or number 2-0.

(d) The fibers of the inguinal, hypogastric, and femoral nerves are resected, using Metzenbaum or Harrington scissors, tissue forceps without teeth, and long-bladed retractors.

(e) The lymphatic node beds may be identified with silk or metal clips. Fine, long, sharp dissection scissors are needed.

(f) The large tissue surfaces are exposed for complete dissection by means of retractors and protected by warm, wet laparotomy packs. High saphenous vein ligation is performed, using scissors, forceps, hemostats, and chromic gut or silk suture ligatures.

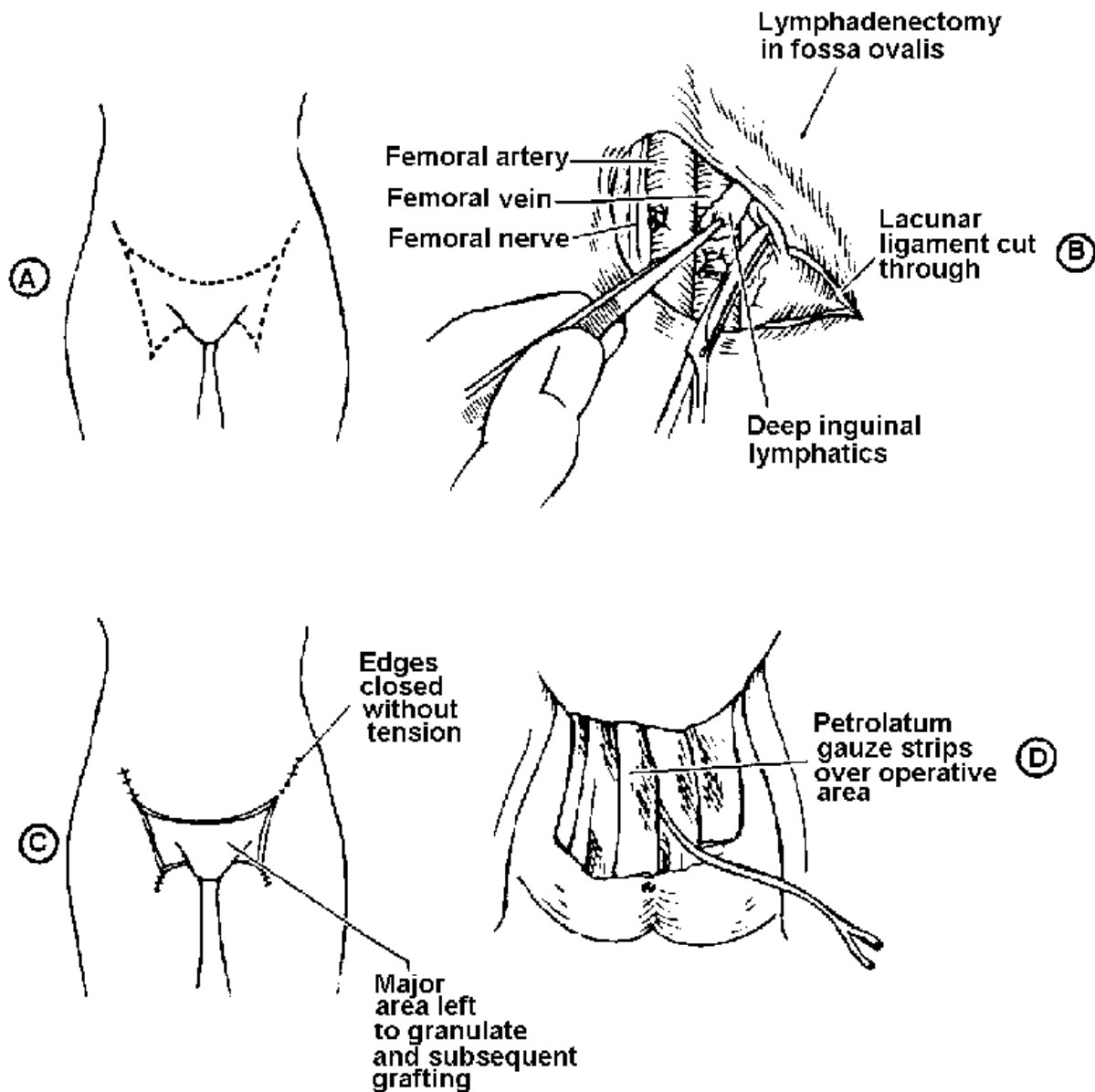


Figure 2-4. Radical vulvectomy and groin lymphadenectomy.

A-Outline of incisional lines for simple or radical operations for vulval cover.

B-Dissection completed, involving nerves, saphenous veins, and muscles when dissection of distal half of femoral canal has been completed.

C-Upper edges of abdominal incisions may be partially closed.

D-With indwelling catheter in bladder, wound is dressed with layers of petrolatum gauze and held in place with light pressure dressing.

(g) The femoral canal is cleaned of its lymphatics, and the round ligament is clamped, cut, and ligated.

(h) The peritoneum is freed from the muscles, fascia is dissected free, deep lymphatic nodes and areolar tissue are removed, and vessels and their attachments are clamped, cut, and ligated, using long curved scissors, long tissue forceps, hemostats, and ligatures.

(i) The lesion is removed. In deep pelvic lymphadenectomy, the ureter may be exposed.

(j) The inguinal canal is reconstructed, and the wound is partially closed, using chromic gut and silk sutures. An indwelling system of urinary drainage is established, and the wound is dressed.

(2) Vulvectomy portion of the surgery.

(a) The skin incisions of the abdomen and thigh join with those for vulvectomy. The incisions in the vulva encircle the urethra.

(b) In the vulval dissection, terminal portions of the urethra and vagina, the mons pubis, clitoris, frenulum, prepuce of the clitoris, and Bartholin's and Skene's glands, plus fascial coverings of the vulva are removed with the specimen.

(c) Reconstruction of the vaginal walls and the pelvic floor is completed. An indwelling system of urinary drainage is established, suction drains are placed into the denuded area, the wound is dressed with layers of petrolatum gauze, and a light pressure dressing is applied.

2-15. VAGINAL PLASTIC OPERATION (ANTERIOR AND POSTERIOR REPAIR)

a. General.

(1) This operation involves reconstruction of the vaginal walls, the pelvic floor, and the muscles and fascia of the rectum, urethra, bladder, and perineum. It involves a vaginal repair to correct a cystocele and/or rectocele, restore the bladder to its normal position, and strengthen the vagina and the pelvic floor.

(2) A cystocele is formed when the portion of the anterior vaginal wall that is between the cervix and the urethra and the base of the bladder herniate inferiorly. The hernia of the bladder protrudes through the torn musculofascial components of the vaginal anterior wall, with protrusion into the vaginal outlet. A defect in the anterior vaginal wall is usually caused by childbirth or an inherent weakness. A large herniation may cause a sensation of pressure in the vagina or present as a mass at or through the introitus.

(3) A rectocele is formed by a herniation of the anterior rectal wall (posterior vaginal wall) into the vaginal outlet. In general, the anterior rectal wall forms a bulging mass beneath the posterior vaginal mucosa. It is created as the mass pushes downward into the lower vaginal canal. The rectum, may be torn from its dense connective tissue, the fascial and muscular attachments of the urogenital diaphragm, and the pelvic wall. The levator ani muscles become stretched or torn. The symptomatic signs are a mass protruding from the vagina, difficulty in evacuating the lower bowel, and a feeling of pressure.

(4) An enterocele is a protrusion of the cul-de-sac of Douglas and some of the pelvic small intestine within the peritoneal sac. It pierces through a weakened area between the attenuated anterior rectal and posterior vaginal walls.

(5) An enterocele may also be seen in multiparous women as part of a massive lesion, in which a large sac contains the bladder, lower portions of the ureters, and the prolapsed uterus. In some cases, a Kelly or Marshall-Marchetti operation may be necessary to treat urinary incontinence and uterine prolapse.

(6) During parturition, the outer fibrous layers of the vagina may be torn, thereby permitting the adjoining viscera to herniate into the vaginal outlet. Because of unrepaired perineal lacerations, gradual pulling apart of the underlying fascia and muscles of the pelvic floor and outlet takes place. The woman has symptoms of relaxation and displacement of the pelvic organs. Accidents, gradual deterioration of tissues, or congenital weakness, may also result in mechanical disturbances of the pelvic structures.

b. **General Operative Procedure.** Dilatation and curettage may be done. The labia are held open with retractors and the cervix is grasped with a tenaculum. Adair forceps are used to retract the cervix; self-retaining or Sims retractors are used to expose the operative site.

c. **Anterior Wall Repair.**

(1) Areolar tissue between the bladder and vagina at the bladder reflection is exposed with the knife handle. The full thickness of the vaginal wall is separated up to the bladder neck, using a knife, curved scissors, tissue forceps, Adair or Allis forceps, and sponges on holders. Bleeding vessels are clamped and tied with ligatures (see figure 2-5 **A**).

(2) The urethra and bladder neck are freely mobilized, using a knife, gauze sponges, and curved scissors (see figure 2-5 **B**), to develop the strong free edge of, the vesicovaginal fascia on each side.

(3) The free edges of the fascia are sutured, using chromic gut sutures number 2-0. Sutures are placed in a manner that after they have been tied, there results

a double inverting of the tissue, a narrowing of the bladder neck, and a delineating of the posterior ureterovesical angle (see figure 2-5 C).

(4) The connective tissue on the lateral aspects of the cervix is sutured into the cervix with chromic gut number 2-0 sutures swaged on curved needles. This is done to shorten the cardinal ligaments.

(5) Allis forceps are applied to the edges of the incision, and the left flap of the vaginal wall is drawn across the midline. Edges are trimmed according to the size of the cystocele (see figure 2-5 D). This process is repeated on the right flap of the vaginal incision. Adair forceps, tissue forceps, and curved scissors are needed.

(6) The anterior vaginal wall is closed with interrupted chromic gut number 2-0 sutures in a manner resulting in reconstruction of an anterior vaginal fornix.

d. Posterior Wall Repair.

(1) Allis forceps are placed posteriorly at the mucocutaneous junction on each side, at the hymenal ring, and just above the anus.

(2) Skin and mucosa are incised and dissected from the musculature beneath, using a knife, tissue forceps, curved scissors, and sponges.

(3) Allis-Adair forceps are placed on the posterior vaginal wall, scar tissue is removed, and dissection is continued to the posterior vaginal fornix and laterally, depending on the size of the rectocele.

(4) The perineum is denuded by sharp dissection; the trimming of the posterior vaginal wall is carried out, using Allis forceps, curved scissors, and sponges on holders.

(5) The free edges of the levator ani muscle on each side are brought together in front of the rectum by insertion of interrupted chromic gut number 0 sutures.

(6) Bleeding is controlled, and the vaginal wall is closed from above downward to the anterior edge of the puborectal muscle, using continuous chromic gut number 2-0 suture. The rectocele is repaired from the posterior fornix to the perineal body. Remains of the transverse perineal and bulbocavernosus muscles are used to build up the perineum. The anterior edge of the levator ani sling may be approximated.

(7) The mucosa and skin are trimmed, and the remaining closure is effected by interrupted sutures. The skin is closed with subcuticular sutures, chromic gut number 2-0.

(8) The vagina is packed with 2-inch vaginal packing. An indwelling urinary drainage system is established. A perineal pad may be applied to the wound and held in place by means of a perineal binder.

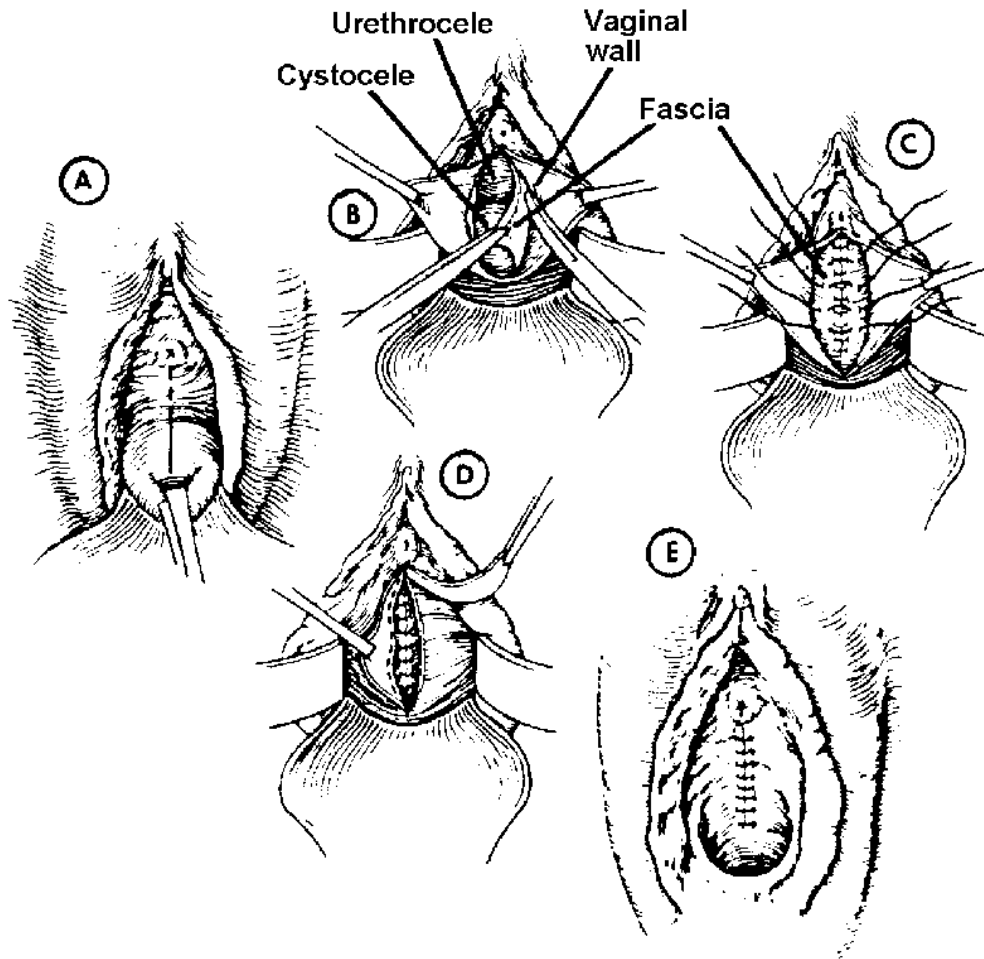


Figure 2-5. Correction of cystourethrocele.

A-Cervix pulled down as far as possible with tenaculum. Vertical incision made entirely through to vaginal wall.

B-Vaginal flaps further dissected upward. Urethral meatus and pubocervical fascia separated from vaginal wall with Mayo scissors.

C-Fascia brought together with continuous surgical chromic suture, beginning at lowest point and ending near external urethral meatus. A few interrupted sutures (chromic gut or silk) placed secondarily.

D-Excess portion of vaginal wall carefully removed, leaving sufficient amount to be closed with tension.

E-Completed operation, maintaining bladder and urethra in normal position.

2-16. VESICOVAGINAL FISTULA REPAIR

a. General.

(1) Through the vaginal outlet, the mucosal tissue of the anterior vaginal wall is dissected free, the opening from the bladder into the vagina is closed, the fascial attachments between the bladder and vagina are repaired, and temporary drainage is established.

(2) The fistulas vary in size from a small opening that permits only slight leakage of urine into the vagina to a large opening that permits all urine to pass into the vagina.

(3) Vesicovaginal fistulas may result from radical surgery in the management of pelvic cancer, from radium therapy without surgery, from chronic ulceration of the vaginal structures, from penetrating wounds, or from childbirth.

(4) A urethrovaginal fistula usually causes constant incontinence or difficulty in retaining urine. This condition occurs after damage to the anterior wall and bladder or following radiation, surgery, or parturition. A ureterovaginal fistula develops as a result of injury to the ureter. In some cases, reimplantation of the ureter in the bladder or ureterostomy may be done.

b. Operative Procedure--Vaginal Approach.

(1) Traction sutures are placed about the fistulous tract; tissues are grasped with Adair forceps and plain tissue forceps.

(2) The scar tissue about the fistula is excised, cleavage between bladder and vagina is located, and clean flaps are mobilized, using scissors, forceps, and sponges.

(3) The bladder mucosa is inverted toward the interior of the bladder with interrupted sutures of chromic gut number 4-0 swaged to fine curved needles held with a Mayo needle holder and tissue forceps. The suture is passed through the muscularis of the bladder down to the mucosa.

(4) A second layer of inverting sutures is placed in the bladder and tied, thereby completely inverting the bladder mucosa toward the interior.

(5) The vesicovaginal fascia is repaired with interrupted number 2-0 chromic gut sutures.

(6) The vaginal wall is closed with interrupted chromic gut sutures in the direction opposite to the closure of the bladder wall.

(7) The bladder is distended with distilled sterile water to determine any leaks. A catheter is left in the bladder; dressings are applied and held in place with a nonirritating plastic tape and a binder.

c. Operative Procedure--Trans-peritoneal Approach.

(1) With the patient in a slight Trendelenburg position, a median abdominal incision is made, as for laparotomy.

(2) The fistulous tract is identified; the vaginal vault and the adjacent adherent bladder are separated with scissors, forceps, and sponges.

(3) The vesicovaginal septum is dissected down to the healthy tissue beyond the site of the fistula.

(4) The fistulous tract is mobilized. The bladder site of the fistula is inverted into the interior of the bladder with two rows of inverting sutures of chromic gut number 4-0. The muscularis and mucosa layers of the vagina are inverted into the vaginal vault by means of two rows of sutures.

(5) The flaps of peritoneum are mobilized both from the bladder and from the adjacent vaginal vault, and are closed to form a new vesicovaginal reflection of peritoneum below the site of the old fistulous tract.

(6) The wound is closed in layers, as for laparotomy. Dressings are applied and held in place with adhesive or plastic tape, and an indwelling catheter is left in the bladder.

2-17. RECTOVAGINAL FISTULA REPAIR--VAGINAL APPROACH

a. General.

(1) This procedure involves vaginal repair of the perineum, fascia, and muscle-supporting structures between the rectum and vagina, thereby closing the fistula formed between the rectum and the vagina.

(2) A rectovaginal fistula occurs between the rectum and the vagina. In the presence of a large rectovaginal fistula, a colostomy may be done.

b. Operative Procedure.

(1) The scar tissue and tract between the rectum and vagina are excised; edges of fresh tissue are approximated with sutures of chromic gut number 4-0.

(2) The rectum and vaginal walls are mobilized; the rectum is closed in layers with inversion of the mucosa into the rectal canal.

(3) The levator ani is approximated between the rectum and vaginal.

(4) The vagina is closed transversely or in a sagittal plane different from that of the rectal canal; the vaginal mucosal layer is inverted into the vaginal wall; an indwelling urinary drainage system is established; and dressings are applied to the wound.

2-18. OPERATIONS FOR URINARY STRESS INCONTINENCE

a. General.

(1) This operation involves the repair of the fascial supports and pubococcygeal muscle surrounding the urethra and the bladder neck. It is done through either a vaginal or an abdominal approach.

(2) Normal micturition (urination) depends on a finely coordinated group of voluntary and involuntary movements. As a result of volitional impulses, voiding may be inhibited or stopped by contraction of the perineal and periurethral musculofascial structures.

(3) The type of operation selected depends on the severity of stress incontinence, the extent of the lesion causing it, the patient's ability to use the anatomical mechanism for voluntary inhibition of urination, and the operations that have already been performed for correcting it. Stages of stress incontinence are classified in relation to frequency and degree of incontinence, the presence of other diseases, and the function of the pubococcygeus muscle (levator ani).

(4) The aim of any operation for urinary stress incontinence is to improve the performance of a dislodged or exhausted bladder neck. The surgeon endeavors to restore or reconstruct the supporting structures, the operation thereby resulting in the effective closure of the bladder neck.

(5) Previous pelvic operations may have resulted in scarring and distortion, with displacement of the bladder neck to an unfavorable position for proper functioning. Conditions such as uterine prolapse, cystocele, urethrocele, cystourethrocele, or urogenital fistulas following therapy may be associated with stress incontinence.

b. Operative Procedure--Vaginal Approach.

(1) A Foley catheter is passed into the bladder. The posterior vaginal wall is retracted, and an incision is made through the anterior vaginal wall down to the urethra and bladder.

(2) The vaginal wall is dissected from the bladder and urethra; the neck of the bladder is sutured together with fine chromic gut. The wound is closed, as described for vaginal repair.

c. Operative Procedure--Vesi-courethral Suspension (Marshall--Marchetti Procedure).

(1) Through a suprapubic abdominal incision, the space of Retzius is entered, and the bladder and urethra are freed from the surrounding structures.

(2) Mattress chromic gut sutures number 1 or Mersilene number 0 are inserted through the supporting fascia of the vaginal wall on either side of the urethra and bladder neck; they are then passed through the muscle associated with the symphysis pubis, thereby providing support to the urethra and bladder neck.

(3) Additional sutures are introduced in the lower and lateral portions of the bladder wall and are attached to the posterior portion of the rectus muscles, thereby pulling the bladder anteriorly to obliterate the space of Retzius.

(4) The wound is closed and may be drained with a Penrose drain.

2-19. EXCISION OF FIBROMA OF THE VAGINA

a. **General.** This procedure involves the removal of the lesion through a transverse or longitudinal incision of the wall of the vagina. Small cysts or small benign tumors that distort the vagina or those that are ulcerated and infected are the kind of lesions removed in this surgery.

b. Operative Procedure.

(1) The vaginal vault is retracted, using lateral and Sims retractors. Traction sutures of chromic gut number 0 or silk number 2-0 are placed on each side of the tumor. The posterior lip of the cervix is grasped with a Jacobs vulsellum forceps and drawn anteriorly to expose the operative site.

(2) The vaginal wall is incised, and the edges are grasped with traction sutures on curved, taper point needles or with Allis forceps.

(3) The cyst and its capsule are excised, using a knife and curved scissors; bleeding vessels are clamped and ligated, using Halsted forceps and fine sutures.

(4) The vaginal incision is closed with interrupted sutures of chromic gut number 2-0, and dressings are applied.

2-20. CONSTRUCTION OF VAGINA

a. **General.** This operation involves taking a skin graft and then using it for vaginal reconstruction to repair or overcome congenital or surgical defect.

b. Operative Procedure.

(1) Skin is taken from the abdomen or anterior thighs. The donor sites are dressed in the routine manner with pressure dressings over nonadhesive gauze.

(2) A vaginal orifice is created by sharp dissection, and a molding is made of dental compound or plastic shaped to size. Donor skin, is sutured over the mold, and the mold is secured in the vaginal opening with sutures and pressure dressings.

2-21. TRACHELORRHAPHY

a. **General.** This operation involves removal of torn surfaces of the anterior and posterior cervical lips and reconstruction of the cervical canal. It is done to treat deep lacerations of a cervix (1) that is relatively free of infection and (2) in women past the childbearing age.

b. Operative Procedure.

(1) The labia are retracted with Allis-Adair forceps or sutures. The cervix is grasped with a Jacobs vulsellum forceps.

(2) The affected tissue of the exocervix is denuded with a knife. The flaps are undermined by means of a knife and curved scissors. Bleeding vessels are clamped and ligated. The mucosa is dissected from the cervix.

(3) A small distal portion of the cervical canal is coned to remove infected tissue by means of a knife. Bleeding vessels are clamped and ligated with chromic gut number2-0 ligatures.

(4) The denuded and coned areas are covered by suturing and mucosal flaps of the exocervix transversely, using six to eight interrupted chromic gut number0 sutures swaged to 1/2-circle, trocar-point needles. Tissue forceps, hemostats, and sponges on holders are needed. The sutures are placed in such a manner that the fibromuscular tissue of the cervix is included, thereby eliminating dead space where a hematoma may form and providing a complete reconstructed cervical canal.

(5) The wound is cleansed and dressings are applied and held in place with a binder. A retention catheter may be introduced in the bladder.

2-22. REMOVAL OF PEDUNCULATED CERVICAL MYOMA

a. **General.** This operation involves the removal of a tumor by the snare method or by dissection from the cervical canal with a knife (or with cold-knife conization). Cervical polyps stem from the endocervical canal. They may vary in size and are soft, red, and friable. Bleeding may result from the slightest trauma. Usually, the surgeon performs an endometrial and endocervical curettage and a cytological smear is taken.

b. Operative Procedure.

(1) The anterior lip of the cervix is grasped with a Jacobs vulsellum forceps. The canal is sounded and dilated to either visualize or palpate the base of the pedicle.

(2) If the pedicle of the tumor is thin, a tonsil snare may be placed over the body of the tumor, permitting the snare to crush the base of the tumor and to control bleeding. If the tumor is large, its base is dissected out with a knife. Bleeding is controlled by the use of warm, moistened gauze sponges on holders.

(3) Retractors are withdrawn; vaginal packing may be introduced into the cervical canal. The tenaculum is removed from the cervix, and a dressing applied and held in place with a binder.

2-23. AMPUTATION OF THE CERVIX

a. **General.** This operation involves the removal of a portion of the portio vaginalis of the cervix. This cervical amputation, without repair of the pelvic floor, is usually done in the presence of an intraepithelial cancer, with preservation of the remainder of the female genital organs. In specific cases, such as mycotic or venereal infections of the cervix, this may be done by excision of the cervix.

b. Operative Procedure.

(1) A dilatation and curettage may be performed before excision of the cervix.

(2) The labia are retracted; the cervix is grasped with a Jacobs tenaculum and drawn sharply downward.

(3) A circular incision is made through the full thickness of the vaginal wall by means of a knife. The distal end of each cardinal ligament is clamped, cut, and ligated, using Heaney clamps, long curved Ochsner forceps, scissors, and chromic gut number 0 ligatures.

(4) A portion of the portio vaginalis of the cervix is amputated by an oblique circular incision; the canal is coned, using a knife. Bleeding vessels are clamped and ligated with chromic gut number 0 ligatures.

(5) Anterior and posterior Sturmdorf sutures of chromic gut number 0 and number 2-0 on 1/2-circle, trocar-point needles are placed. Bleeding vessels are clamped and ligated.

(6) The vaginal wall flaps are approximated, covering the denuded cervix by means of six to eight interrupted chromic gut number 2-0 and 0 sutures swaged to 1/2-circle, taper point needles. The patency of the cervical canal is tested, using a

sound; urinary drainage may or may not be established; vaginal dressings are applied and held in place with nonirritating plastic tape and a binder.

2-24. DILATATION OF THE CERVIX AND CURETTAGE

a. **General.** The dilatation of the cervix and curettage (D AND C) operation involves the introduction of instruments through the vagina into the cervical canal and then into the uterus and, in some cases, removal of substances and blood. It is done either for diagnostic purposes or as a form of therapy for a variety of pelvic conditions such as incomplete abortion, abnormal uterine bleeding, or primary dysmenorrhea. A D and C may be performed when carcinoma of the endometrium is suspected, in the study of infertility, or prior to amputation of the cervix or an operation for prolapse of the uterus.

b. Operative Procedure.

(1) A Kelly or Auvard retractor is placed posteriorly in the vagina. A Sims or Kelly retractor is placed anteriorly to expose the cervix. The anterior lip of the cervix is grasped with a tenaculum.

(2) The direction of the cervical canal and the depth of the uterine cavity are determined by means of a blunt probe or graduated pliable uterine sound.

(3) The cervix is gradually dilated by means of graduated Hegar or Hand dilators and a Goodell uterine dilator.

(4) Exploration for pedunculated polyps or myomas may be done, using a polyp forceps.

(5) The interior of the cervical canal and the cavity of the uterus are curetted to obtain either a fractional or a routine specimen. For specific identification of the site of specimens, the endocervix is scraped with the curette first, and the specimen is separated from the curettings of the uterine endometrium. In a routine curettage, all curettings are sent together for identification of tissue cells.

(6) Fragments of endometrium or other dislodged tissues are removed with warm, wet gauze sponges on holders.

(7) Multiple punch biopsies of the cervical circumference (at 12, 3, 6, and 9 o'clock) may be taken with the Gaylor biopsy forceps to supplement the diagnostic workup.

(8) Retractors are withdrawn; packing of iodoform or plain gauze secured to dressing forceps may be inserted into the cavity. The tenaculum is removed from the cervix. A perineal pad is applied.

2-25. UTERINE ASPIRATION (SUCTION CURETTAGE)

a. **General.** This operation involves the vacuum aspiration of the contents of the uterus. This has proven to be a safe and effective method for early termination of pregnancy and for use in missed and incomplete abortions. Advantages include less dilatation of the cervix, less damage to the uterus, less blood loss, less chance of uterine perforation, and reduced danger of infection.

b. **Patient Preparation.** The patient is placed in the lithotomy position under general anesthetic. An external and internal vaginal prep is done.

c. Operative Procedure.

(1) The cervix is exposed using an Auvarad weighted speculum and an anterior retractor; then the cervix is grasped with a sharp tenaculum and drawn toward the introitus (see figure 2-6).

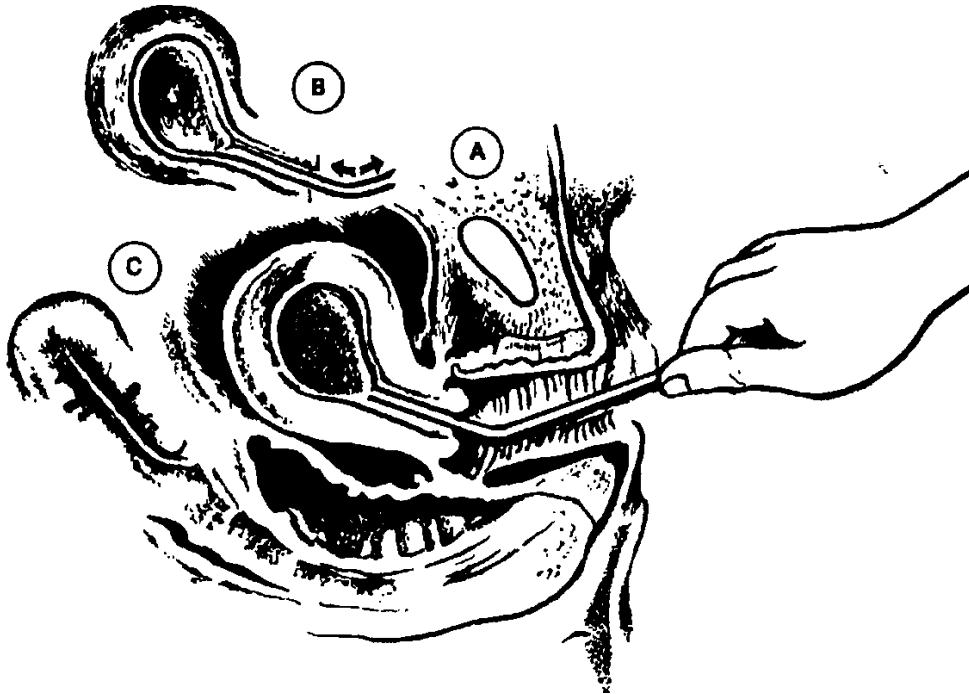


Figure 2-6. Uterine aspiration. **A**-Insertion of the cannula. **B**-Gentle suction motion to aspirate contents. **C**-Uterus evacuated.

(2) The cervix is dilated in the routine manner, allowing 1 mm of cannula diameter for each week of pregnancy.

(3) The appropriate sized cannula is then inserted into the uterus until the sac is encountered. The vacuum is turned on with immediate disruption and aspiration of the contents. Continued gentle motion of the cannula will remove the entire uterine contents.

(4) Depending on the diagnosis, conventional curettage may then be employed.

(5) Retractors and tenaculum are withdrawn; a perineal pad is applied.

(6) The specimen is contained in the vacuum bottle, from which it is removed for laboratory examination.

2-26. SHIRODKAR OPERATION (POSTCONCEPTIONAL)

a. **General.** This operation involves the placement of a collar-type ligature or other material at the level of the internal os to close it. It is made necessary by incompetence of the cervix, a condition characterized by habitual midtrimester spontaneous abortions. The operation is designed to prevent the cervical dilatation that results in release of uterine contents.

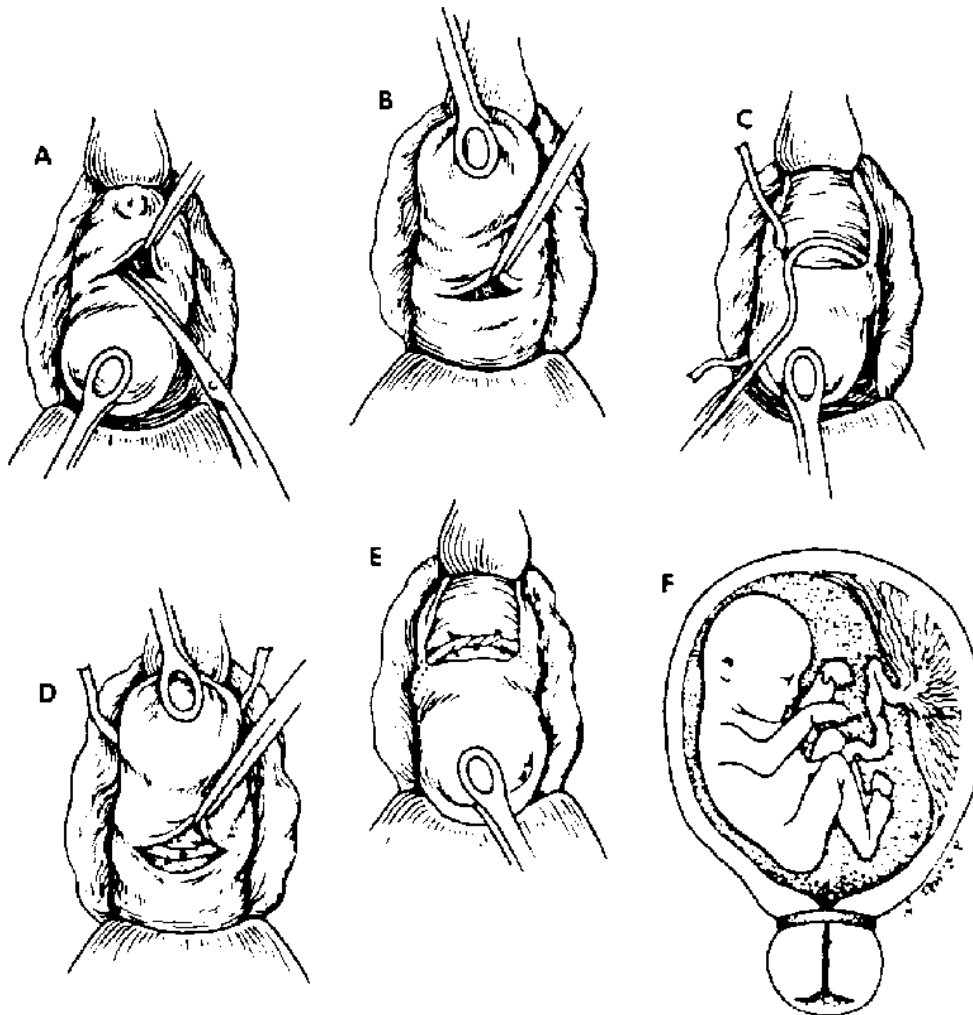


Figure 2-7. Principles of Shirodkar operation for treatment of incompetent internal cervical os during pregnancy.

b. Operative Procedure (see figure 2-7).

(1) Anterior and posterior vaginal retractors are placed, and the cervix is pulled down with smooth ovum or sponge forceps. With thumb forceps and dissecting scissors, the mucosa over the anterior cervix is opened to permit the bladder to be pushed back.

(2) The cervix is lifted, and the posterior vaginal mucosa is similarly incised at the level of the peritoneal reflection. With ligature carriers, the lateral mucosa is tunneled on either side.

(3) The prepared ligature is placed at the desired level and anchored posteriorly with silk suture, then drawn tight in front to close the cervix. The suture is tied.

(4) The collar ligature is anchored with silk sutures anteriorly. The anterior and posterior mucosal incisions are closed with chromic sutures number 0 or number 2-0 to complete the procedure.

2-27. CONIZATION AND BIOPSY OF THE CERVIX

a. General.

(1) This procedure is the removal of diseased cervical tissue to treat strictures of the cervix and chronic cervicitis. The conization may be performed either by scalpel resection and suturing or by the application of cutting electrosurgical current with an active electrode inserted into the cervical canal.

(2) Endometrial biopsy is done to determine the menstrual phase and carry out histological study of the endometrium. Scalpel conizations are done for diagnostic purposes, such as when the patient has a positive Papanicolaou (Pap) smear. Conization of the cervix may be done in some cases in which hysterectomy is indicated and in which benign disease of the cervix is present. It may also be done in those cases in which total hysterectomy is not feasible.

b. Operative Procedure.

(1) The posterior vaginal wall is retracted by a speculum and the anterior vaginal wall by lateral retractors. The outer portions of the cervix are grasped with a tenaculum, and the cervix is drawn toward the introitus; then the anterior speculum is removed. Cystic cervix may be treated with a needle electrode. Endometrial biopsy may be done. Bleeding points may be coagulated.

(2) For cauterization, the electrode is passed into the cervical canal, and the diseased membrane is removed. In patients with a positive Pap smear, the cervical cone is excised with a scalpel and bleeding controlled by coagulation and pressure.

(3) The cervical canal is cleansed with an antiseptic solution. If a wide conization is performed, the cervix may be sutured.

2-28. RADIUM INSERTION FOR CERVICAL MALIGNANCY

a. **General.** This procedure involves the insertion of radium into the cervix for the treatment of cancer. The procedure may be accomplished with X-ray film control to ensure accurate placement of the radium. Precautions to protect personnel from undue exposure are taken, and the procedure is monitored by the radiology department.

b. **Operative Procedure--Intravaginal or Intrauterine Application.** The bladder is identified and decompressed by inserting a Foley catheter. The Foley bag is inflated with a radiopaque medium such as conray for visualization. The patient is placed on an X-ray table or operating table with a cassette, and radium is inserted.

c. **Operative Procedure--Interstitial Application.** Radium and cobalt needles are available in various lengths with a small diameter for insertion into the tissue surrounding the cervix. They are inserted vaginally with a needle applicator and are used as a supplement to intravaginal or intrauterine sources. To facilitate removal, the needles have wires or threads attached to their distal end.

2-29. CULDOSCOPY

a. **General.** The diagnostic procedure provides visualization of pelvic structures through a tubular instrument similar to a cystoscope, which is introduced through a small incision in the posterior vaginal cul-de-sac. Direct observation of the passage of dye from the uterus through the fimbriated ends of the tube is possible with the culdoscope to help determine tubal patency, the presence of ectopic pregnancy, unexplained abdominal or pelvic pain, the nature of pelvic masses, and to evaluate normal functioning of the genital tract. This examination may enable the surgeon to avoid unnecessary pelvic surgery. Laparoscopy is the preferred procedure today.

b. **Patient Preparation.** The patient is prepared as for a vaginal operation (refer to paragraphs 2-12 and 2-13). A local or regional anesthetic may be used. When a general anesthetic is used, the patient is intubated. The patient is usually placed in a knee-chest position, kneeling on the footboard with a kneestrap around the thighs, the chest supported on pillows, and the arms comfortably flexed above the head.

c. **Operating Room Preparation.** Instruments may be placed on a table so that the surgeon may serve himself. However, there is still need for a circulator. The lens of the scope may fog if the instrument is introduced cold, so the tip is dipped in warm water and wiped dry before being used.

d. **Operative Procedure** (see figure. 2-8).

(1) The trocar of the culdoscope is inserted into the fornix behind the cervix; the trocar is then introduced into the pelvis between the two uterosacral ligaments.

(2) The trocar is withdrawn from the sheath; the sterile culdoscope is inserted through the sheath. The culdoscope does not touch the vaginal mucous membrane thus reducing the possibility of infection to a minimum.

(3) The uterus, tubes, broad ligaments, uterosacral ligaments, rectal wall, sigmoid, and small intestine may be visualized through manipulation of the scope (see figure 2-8).

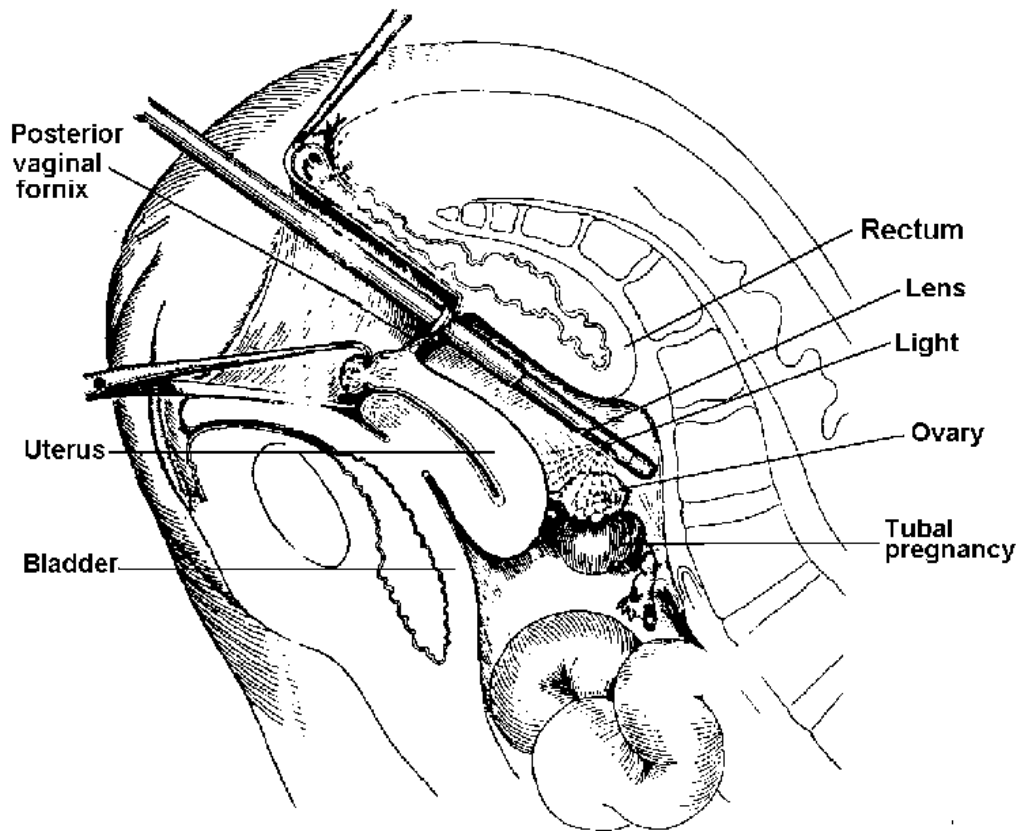


Figure 2-8. Culdoscope. Sagittal section showing culdoscopy viewing pelvic viscera.

(4) In the study of sterility, a self-retaining screw-lipped cervical cannula is introduced in the cervical canal, and it is connected by a plastic tube to a syringe containing a dye. If the uterine tube is patent, the dye solution is seen dripping from the fimbriated end.

(5) The culdoscope is withdrawn, the sheath is left in place, and the patient is placed on her side. Pressure is exerted on the abdomen to force the air out of the peritoneal cavity, thereby eliminating postoperative discomfort and potential air embolus. The vaginal wound is not sutured. The patient is returned to bed.

2-30. EXCISION OF BARTHOLIN DUCT CYST OR ABSCESS

a. **General.** This procedure consists of removing or incising and draining the cyst through the vaginal outlet. A cyst in the vulvo- vaginal gland usually follows acute infection and is treated by marsupialization when it is quiescent. Such cysts are nonneoplastic and result from retention of glandular secretions due to blockage somewhere in the duct system.

b. **Operative Procedure.**

(1) The labia minora are sutured to the perineal skin on each side to expose the vaginal introitus. Silk or plain gut sutures swaged to 3/8-circle, cutting edge needles on a needle holder, tissue forceps, and suture scissors are needed.

(2) An elliptical incision is made in the mucosa, which is distended over the cyst.

(3) The cyst wall is dissected and blunt-pointed scissors are used for complete removal of the gland. A drain may be inserted, and a dressing or perineal pad is applied.

2-31. COLPOTOMY

a. **General.** Needle culdocentesis is the insertion of an aspirating needle through the posterior fornix of the vagina. Posterior colpotomy is an incision through the vagina and peritoneum and the removal of pus and blood. The needle procedure is done to diagnose ectopic pregnancy or to detect intraperitoneal bleeding or cul-de-sac hematoma. Posterior colpotomy is done to evacuate pus and establish drainage from a cul-de-sac abscess or tubo-ovarian abscess, or in a search for blood when a tubal pregnancy is suspected.

b. **Operative Procedure.**

(1) For needle culdocentesis, a 15-gauge needle attached to a syringe is inserted through the posterior fornix of the vagina. Suspected intraperitoneal bleeding is confirmed if dark or red blood flows freely into the syringe. Failure to obtain blood does not rule out the possibility of pregnancy completely.

(2) For posterior colpotomy, a transverse incision using angular blade scissors is made through the vagina and peritoneum behind the cervix at the superior point of the posterior fornix. The cul-de-sac is punctured with a long Rochester-Pean hemostat. The jaws of the hemostat are spread apart to enlarge the opening and permit the flow of liquid from the cul-de-sac. The cavity is explored; drains may be inserted.

(3) In either procedure, bleeding of the vaginal wall is controlled by sutures of chromic gut number 2-0; dressings are applied to the wound surface and held in place with a binder.

2-32. FOTHERGILL-HUNTER OPERATION FOR PROLAPSE OF THE UTERUS

a. **General.** This procedure, following D and C, involves a complete repair of the vaginal walls. This is done from above downward, correcting faulty supportive structures of the pelvic floor. It is usually done on women of childbearing age who desire preservation of the childbearing function.

b. Operative Procedure.

(1) Dilatation of the cervix and curettage of the uterus is done, as previously described in paragraph 2-24.

(2) An inverted V incision is made through the full thickness of the vaginal wall. It extends from the bladder reflection to the urethral meatus.

(3) The cervix is circumscribed and bleeding vessels ligated. A knife, Allis-Adair forceps, hemostats, tissue forceps, moist sponges on holders, and chromic gut number 2-0 ligatures are used.

(4) The mucosal flaps are dissected free laterally and posteriorly to expose the cardinal and uterosacral ligaments, which are clamped, ligated, and cut close to the cervical sutures. The cardinal and uterosacral ligaments containing vesical arteries are secured with chromic gut number 0 or 2-0 sutures swaged to 112- circle, taper-point needles.

(5) The cervix is amputated at a site to permit shortening of the ligament. The remaining portion of the cervix is grasped with a Jacobs vulsellum forceps. The rectovaginal septum is exposed by blunt and sharp dissection.

(6) The upper portion of a rectocele is repaired, as described for posterior vaginal plastic repair. A wedge-shaped incision is made with a knife in the portion of vaginal wall to be removed. Repair is performed, using an inverting suture to bring the flaps of the vagina over the sutured fibromuscular tissue of the cervix. Interrupted sutures, chromic gut number 0 swaged to 1/2- circle, trocar-point or taper-point needles are placed to approximate the posterior wall.

(7) Cardinal ligaments are sutured in the midline with interrupted sutures of chromic gut number 0 to shorten the parietal connective tissue, thereby permitting them to provide more support for the pelvic floor.

(8) An anterior and posterior Sturmdorf-type suture is placed in the upper and lower vaginal wall. Flaps are grasped with Allis forceps, the excised vaginal wall is

resected on each side using Metzenbaum scissors, and the anterior vaginal wall is closed and reconstructed.

(9) A plastic reconstruction of the genital aperture is done, using interrupted chromic gut number-0 and 2-0 sutures. The musculature of the perineum is reconstructed by placement of sutures in such a way that the bulbocavernosus and the remaining transverse perineal muscles decrease the genital aperture and add support of the pelvic viscera.

(10) A urinary drainage system is established, packing is placed in the vagina, and vaginal dressings are applied.

2-33. COLPOCLEISIS (LE FORT OPERATION) FOR PROLAPSE OF THE UTERUS

Colpocleisis is the closure of the vagina by approximation of the anterior and posterior vaginal walls, with or without an attendant vaginal hysterectomy. The patient must be apprised of the fact that she will no longer possess a functioning vagina.

2-34. VAGINAL HYSTERECTOMY

a. **General.** In this procedure, the uterus is removed through an incision in the vaginal wall. This may be done unless there is pelvic malignancy or a large uterine tumor, both of which call for abdominal surgery.

b. Operative Procedure.

(1) The labia are retracted back with sutures of silk or chromic gut number 2-0 swaged to 3/8 circle, cutting-edge needles held by Crile short needle holders. Tissue forceps and suture scissors are needed. An Auvard or Sims vaginal retractor is inserted to retract the vaginal wall.

(2) A D and C is performed.

(3) A Jacobs vulsellum forceps or chromic gut number 0 suture ligature is placed on both the posterior cervical lips to permit traction of the cervix.

(4) The vaginal wall is incised. The incision is made anteriorly on the cervix through the full thickness of the wall. The bladder is pushed off the cervix by the knife handle; the bladder is freed from the anterior surface of the cervix and positioned with Kelly retractors.

(5) The vesicouterine peritoneum is carefully opened and the incision is extended laterally as far as the broad ligament. The body of the uterus and the adnexa are palpated and the fundus is delivered through the opening.

(6) The vaginal incision is carried around the cervix; the posterior wall flaps are grasped with Allis forceps. The cul-de-sac peritoneum is opened with a knife. A suction set and small laparotomy packs may be used. The peritoneal edges are sutured to the posterior wall with silk or chromic traction sutures swaged to 1/2- circle, taper-point needles secured on Crile-Wood needle holders.

(7) The uterosacral ligaments containing blood vessels are doubly clamped, ligated, and cut. The ends of the ligatures are left long and tagged with a clamp.

(8) The uterus is drawn downward and the bladder held away with retractors and moist small laparotomy packs.

(9) If the bladder is entered, the opening is closed with two layers of interrupted chromic gut number 4-0 sutures swaged to 1/2- circle, taper-point needles secured to long needle holders. The vesicouterine reflection is sutured to the anterior vaginal wall by means of traction sutures and free ends held in a clamp.

(10) The cardinal ligament on each side is doubly clamped, cut, and doubly ligated. The uterine arteries are doubly clamped, cut, and ligated.

(11) The fundus is delivered through the anterior route with the aid of a uterine tenaculum.

(12) When the ovaries are to be left, a Kocher clamp is placed from below and two from above to grasp the pedicles, which are then cut and doubly ligated on both sides; the uterus is removed.

(13) The peritoneum between the rectum and vagina is approximated with a continuous suture of chromic gut number 2-0. The retroperitoneal obliteration of the cul-de-sac is done by sutures that pass from the vaginal wall through the infundibulopelvic ligament and round ligament, through the cardinal ligament, and out through the vaginal wall. The suture is tied on the vaginal aspect of the new vault. The uterosacral ligament on each side is sutured in the midline. The round, cardinal, and ureterosacral ligaments may be individually approximated for additional support.

(14) An existing rectocele and the perineum are repaired, as described for vaginal plastic repair. In the presence of prolapse, reconstruction of the pelvic floor is done.

(15) An indwelling system of urinary drainage is established; the vagina may be packed; and a perineal pad is applied.

Section III. ABDOMINAL GYNECOLOGICAL AND OBSTETRICAL SURGERY

2-35. LAPAROSCOPY (PERITONEOSCOPY, CELIOSCOPY)

a. **General.** This procedure involves the endoscopic visualization of the peritoneal cavity through the anterior abdominal wall after the establishment of a pneumoperitoneum. It provides the gynecologist the same anatomical view of the pelvic organs as is seen at the diagnostic laparotomy. The pathological condition can be seen, the ancillary procedures such as aspiration of cysts, tubal plastics, and tissue biopsies can be performed. Hemostasis can readily be obtained by using the active electrode probe. This procedure may enable the surgeon to avoid unnecessary pelvic surgery.

b. **Preparation of Patient.** The patient is placed in the supine position, given general anesthetic, and skin prepped as for a laparotomy. A Foley catheter is inserted, and the table is placed in extreme Trendelenburg position with shoulder braces correctly placed.

c. **Operative Procedure.**

(1) A 1-cm incision is placed below or to the left of the umbilicus.

(2) The skin is elevated with hooks. The trocar and valve sleeve are inserted first subcutaneously, then thrust boldly through the remaining layers of the abdominal wall into the peritoneal cavity. The angle taken by the trocar is approximately 45° toward the concavity of the pelvis.

(3) The trocar is removed, the valve sleeve closed, the rubber tubing from the gas source attached, and a pneumoperitoneum produced. Care must be taken to prevent overdistention of the abdomen.

(4) After the patient is placed in the Trendelenburg position, the laparoscope is introduced and inspection begun. Should the biopsy or cautery forceps be needed, they are introduced by trocar through a separate small incision in the abdomen.

(5) The scopes are withdrawn; gas is allowed to escape from the sleeve before it is withdrawn. Subcuticular closure of the skin is followed by the application of a small dressing.

2-36. TOTAL ABDOMINAL HYSTERECTOMY

a. **General.** This operation involves the opening of the abdomen and the peritoneal cavity, with removal of the entire uterus, including the corpus and the cervix. It is done in the presence of fibroids (myomas) of the uterus resulting in uncontrollable bleeding, degeneration, or in some cases, endometriosis or adenomyosis that is far advanced. Total hysterectomy is also indicated in older women with endometriosis

when the bowel and bladder are involved and there is impairment of the normal function of the urinary and gastrointestinal tracts.

b. Preparation of the Patient. An internal and external vaginal prep precedes the skin prep. A Foley catheter is inserted to provide constant bladder drainage during the operation. The supine and high Trendelenburg positions are used.

c. Operative Procedure.

(1) As the skin is incised, the head and upper section of the operating table are lowered slowly, approximately 10° at a time. When the peritoneal cavity is opened, as described previously for laparotomy, the patient is in the desired position for pelvic surgery.

(2) In cases of obese patients or for exploration of the upper abdominal cavity, a left rectus or midline incision is made. For simple hysterectomy, a Pfannestiel incision may be used. The abdominal layers and the peritoneum are opened as for laparotomy.

(3) The round ligament is grasped with Allis-Adair forceps, clamped with curved Rochester-Pean hemostats, and ligated with medium silk or chromic gut sutures swaged to 1/2- circle, taper-point needles secured on long needle holders. Pedicles are cut with Metzenbaum scissors; sutures are tagged with a hemostat to be used as traction later. The procedure is done on both sides.

(4) The uterus is pulled upward, exposing the anterior surface of the uterus, and the peritoneum at the cervicovesical fold is incised.

(5) By use of the surgeon's fingers, the layer of the broad ligament close to the uterus is separated on each side; bleeding vessels are clamped and ligated. The fallopian tube and the utero-ovarian ligaments are doubly clamped together with Ochsner or Carmalt clamps or Heaney hemostats, cut with a knife, and tied doubly with suture ligatures.

(6) The uterus is pulled forward to expose the posterior sheath of the broad ligament that is incised with knife and Metzenbaum scissors. Ureters are identified. The uterine vessels and uterosacral ligaments are doubly clamped with Ochsner, Heaney, or Carmalt hemostats, divided with a knife at the level of the internal os, and doubly ligated with suture ligatures.

(7) The severed uterine vessels are bluntly dissected away from the cervix on each side with the aid of sponges on holders, scissors, and tissue forceps.

(8) The bladder is separated from the cervix and upper vagina with a knife or scissors and blunt dissection assisted by sponges on holders.

(9) The bladder is retracted with a laparotomy pack and a retractor with an angular blade. The vaginal vault is incised with a knife close to the cervix.

(10) The anterior lip of the cervix is grasped with an Allis or tenaculum forceps. With Metzenbaum scissors, the cervix is dissected and amputated from the vagina. As the vagina is opened, the anterior and posterior walls are approximated with Allis or Teale forceps. The uterus is removed. Potentially contaminated instruments used on the cervix and vagina are placed in a discard basin and removed from the field (including sponge forceps and suction). Bleeding is controlled with hemostats and sutures.

(11) The vaginal vault is reconstructed with chromic interrupted sutures. Angle sutures anchor all three connective tissue ligaments to the vaginal vault.

(12) Vaginal mucosa is approximated with a continuous chromic gut suture swaged to a 3/8-circle needle on a long needle holder. The muscular coat of the vagina is closed with figure-of-eight sutures to make the vault of the vagina firm and provide resistance against prolapse.

(13) The peritoneum is closed over the bladder, vaginal vault, and rectum. The laparotomy packs are removed, and the omentum is drawn over the bowel.

(14) The abdominal wound is closed in the regular way.

2-37. SUBTOTAL (SUPRACERVICAL) HYSTERECTOMY

Through an abdominal incision, the peritoneal cavity is opened and the body of the uterus is removed, leaving the cervix in place. This subtotal hysterectomy is seldom done in modern gynecology, except in emergencies to terminate a procedure because of shock or cardiac arrest or in abdominal carcinomatosis in conjunction with the removal of the primary tumor in the ovary.

2-38. ABDOMINAL MYOMECTOMY

a. **General.** This operation involves the removal of fibromyomas from the uterine wall through an abdominal incision. It is usually done in young women with symptoms that indicate the presence of tumors and who have had no children. The tumors may be removed because of infertility or habitual abortion or because of distortion of the bladder and other organs. Myomectomy may be performed in conjunction with other abdominal pelvic surgery as a prophylactic measure.

b. Operative Procedure.

(1) The patient is prepared as for abdominal hysterectomy. A midline or Pfannenstiel incision is used and the uterus exposed.

(2) To contract the musculature of the uterine wall, a suitable drug may be injected into the fundus. If the tumor is riding over the bladder or to free the ligament from the tumor, the round ligament may be doubly clamped, cut, and ligated, as in hysterectomy. The broad ligament may be opened to determine the course of the ureter or to free the bladder by means of curved hemostats and Metzenbaum scissors.

(3) An incision is made in the uterine wall down to the fibroid tumor which is grasped with a tenaculum.

(4) Each tumor is shelled out of its bed, using blunt and sharp instruments. Bleeding vessels are controlled by deep interrupted sutures number 2-0 chromic gut.

(5) The uterus is reconstructed with interrupted chromic gut number 2-0 sutures swaged to 3/8- circle trocar-point needles held on long needle holders.

(6) The round ligament is reapproximated by several interrupted sutures, and the anterior sheath of the broad ligament is closed. The perimetrium is closed over the operative site. The abdominal wound is closed.

2-39. UTERINE SUSPENSION

a. **General.** The operation involves the shortening of ligaments by suturing to muscle structures through an abdominal incision. Uterine suspension is rarely done today, except as part of the conservative surgical treatment of some types of pelvic inflammatory disease or endometriosis when the uterus is bound down on the cul-de-sac.

b. Operative Procedure.

(1) The abdomen is opened, as for myomectomy as stated in paragraph 2-38.

(2) As part of salpingectomy, a modified Coffey suspension may be done to hold the uterus forward and suspend the ovaries so that they cannot prolapse into the cul-de-sac. The round ligaments are sewn toward the bladder. The wound is closed in layers as for laparotomy.

2-40. OOPHORECTOMY AND OOPHOROCYSTECTOMY

a. **General.** Oophorectomy is the removal of an ovary. Oophorocystectomy is the removal of an ovarian cyst. A wide variety of tumors, both benign and malignant, are found in ovaries. Functional cysts comprise the majority of the ovarian enlargements, follicle cysts being the most common. The choice of operation depends on the patient's age and symptoms, findings on physical examination, and direct examination of the adnexa during exploration. If the ovarian tumor is recognized as benign, only the visibly diseased portions of the adnexa are removed. In the presence

of dermoid, follicle, and corpus luteum cysts, the cyst is usually enucleated, and most of the ovarian parenchyma is preserved. In tubal pregnancy, the pregnant tube is removed and, in some cases, the ovary also.

b. **Operative Procedure.** The abdominal peritoneal cavity is opened, the cyst is removed.

(1) For removal of a large ovarian cyst, a purse-string silk suture is placed in the cyst wall, and a trocar is introduced in its center; the suture is tightened around the trocar as the fluid is aspirated. The trocar is removed, and the purse-string suture is tied. All normal ovarian tissue is preserved.

(2) For removal of dermoid cyst, the field is protected with laparotomy packs, since the contents of such cysts produce irritation if they are spilled into the peritoneal cavity. An incision is made along the base of the cyst between the wall and the normal ovarian tissue. The cyst is dissected free and removed intact. The ovary is closed with interrupted fine chromic gut sutures.

(3) For decortication of the enlarged ovary and bridge resection, a large segment of the ovarian cortex opposite the hilum is removed. The cysts are punctured with a needle point and collapsed. A wedge of ovarian stroma, extending deep in the hilum, is resected with a small knife; the cortex of the ovary is closed with interrupted chromic gut number 3-0 suture.

(4) To prevent prolapse of the tube into the cul-de-sac, it may be sutured to the posterior sheath of the broad ligament.

(5) The abdominal wound is closed as for laparotomy.

2-41. SALPINGO-OOPHORECTOMY

a. **General.** This operation is the removal of a tube and all or part of the associated ovary. It may be done in some young women who are anxious to have children after all other methods of treatment have failed to cure chronic salpingo-oophoritis, in patients with ectopic tubal gestation, or in those with tuberculosis of the adnexa or large adnexal cysts. If both tubes and ovaries are diseased, they are removed with total hysterectomy.

b. **Operative Procedure.**

(1) The abdominal wall and peritoneal cavity are opened, as for laparotomy.

(2) The affected tube is grasped with Allis or Babcock forceps. The infundibulo-pelvic ligament is clamped with Mayo hemostats, cut, and ligated with chromic gut number 0 or number 2-0, swaged to a 1/2-circle, taper-point needle, or number 2-0 silk on a French-eye needle.

(3) The mesosalpinx is grasped with Kelly hemostats and divided with the suspensory ligament of the ovary.

(4) The cornual attachment of the tube is excised with a knife or curved scissors. Bleeding vessels are controlled with suture ligatures.

(5) The edges of the broad ligament are peritonealized from the uterine horn to the infundibulopelvic ligament, as for hysterectomy.

(6) The wound is closed as for laparotomy; dressings are applied and held in place with adhesive or plastic tape.

2-42. SALPINGOSTOMY (TUBAL PLASTY)

a. **General.** This operation involves the removal of the obstructed portion of the tube and suspension of the remaining portion to the side of the pelvic wall or placement of it into the uterine cavity. These procedures are for the purpose of restoring fertility.

b. **Operative Procedure.** One of several techniques is carried out after salpingectomy has been performed. The Estes technique or some modification of it is usually followed. In the Estes technique, the convex surface of the ovary is excised and implantation of the remainder is made in the myometrium, communicating with the cavity.

2-43. TUBAL LIGATION

a. General.

(1) This operation is the interruption of fallopian tube continuity, resulting in sterilization of the patient. In general, the indications for sterilization can be divided into three groups: psychiatric, medical, and obstetrical and gynecological. Evaluation and recommendation of sterilization is made by the attending physician. A sterilization permit and a procedure consent form must be signed by both the husband and wife.

(2) The optimum time for sterilization is approximately 24 hours after vaginal delivery, but an objection to this is that the danger of hemorrhage still exists soon after delivery. If a cesarean section is done, the tubes are ligated at this time; with a normal delivery, tubal ligation is done on the first to third postpartum day.

b. **Patient Preparation.** The patient is placed in a supine position and a catheter placed in the bladder. Skin prep and draping is as for laparotomy.

c. Operative Procedure.

(1) The location of the fundus is determined, and a midline incision is made approximately 2 inches below it. The abdomen is opened in the usual manner.

(2) Each tube is delivered and grasped with two Babcock forceps and clamped with two Crile forceps.

(3) The section between the Babcock forceps is resected with Metzenbaum scissors and saved as a specimen. Each tube is doubly ligated with silk sutures number 2-0 about 1 inch from the uterine cornu. The sutures on the proximal end of the tube are left long. This tubal stump is then mobilized by dissecting it free from the mesosalpinx.

(4) A very small cut is made in the serosa on the posterior surface of the uterus near the cornu, and the musculature is penetrated with a Crile forceps for about 1/2 inch, spreading the clamp sufficiently to admit the tube.

(5) One of the ligatures attached to the tubal stump is threaded on a needle, sutured to the bottom of the pocket and carried out to the uterine surface. The other suture attached to the tubal stump is treated in a similar manner. Traction is placed on the sutures, thus the tubal stump is buried in the uterine musculature.

(6) The sutures are tied together, and silk sutures number 4-0 are used to close the edges of the pocket more tightly about the tube. The end of the tube may also be buried within the leaves of the broad ligament.

(7) The abdominal incision is closed in layers and the wound dressed.

2-44. CESAREAN SECTION

a. General.

(1) This operation involves the delivery of an infant through an incision made in the abdominal and uterine walls. This procedure is indicated in instances of previous section, primary and secondary uterine dystocia, cephalopelvic disproportion, placenta previa, abruptio placentas, toxemia, fetal distress (prolapsed cord), diabetes, Rh sensitization, tumors, previous vaginal surgery, abnormal presentation, and many others. In some instances, the cesarean section may be scheduled according to the estimated date of confinement, estimated fetal weight, and definite auscultation of fetal heartbeat at or before 20 weeks from the last menstrual period. At other times, Cesarean section may be performed on an emergency basis.

(2) Several methods for abdominal delivery are accepted: classic cesarean section, low or cervical cesarean section, extraperitoneal operation, and cesarean hysterectomy. The low segment section is today considered standard; however, the classic method may be chosen in some circumstances.

b. Patient Preparation.

(1) The extent of preoperative planning and preparation will depend on the urgency of the delivery and should be paced accordingly. Whole blood should be available. When the patient arrives in surgery, she may or may not be in labor. The circulator should auscultate the fetal heart tone with a fetoscope. The patient is positioned supinely on the table, and restraints are applied; the patient is never left unattended. A Foley retention catheter is inserted and connected to gravity drainage. Choice of anesthetic agent is made by the anesthesiologist after reviewing the condition of the mother and fetus.

(2) Adequate personnel should be available to individually care for the mother and child, since simultaneous urgent needs may arise.

c. Operative Procedure (Low Cervical Method).

(1) A 12- to 15-cm long skin incision is made from below the umbilicus to above the symphysis. As the incision is continued through the fascia and rectus muscles to expose the lower portion of the cervix, blood vessels may be clamped with Crile forceps and ligated with plain gut suture number 3-0.

(2) The exposed peritoneum is incised transversely with a scalpel and Metzenbaum scissors between the two round ligaments. By blunt dissection, the bladder is freed and retracted with the universal DeLee retractor to expose the lower segment of the uterus.

(3) Using a new scalpel blade and bandage scissors, the uterus may be opened either transversely in the manner of Kerr or longitudinally in the manner of Kronig. Using the Kerr technique, a lunar incision is made through the myometrium extending to within one inch of each uterine artery.

(4) The membranes are ruptured and suction immediately applied.

(5) The fetal head is delivered by inserting a hand between the head and the symphysis, rotating the face posteriorly, and exerting upward traction. With the Kronig technique, the face is rotated anteriorly.

(6) The fetal body is delivered. The cord is double cross clamped with Rochester-Pean forceps and cut with bandage scissors. The baby is given to the assistant (pediatrician) for resuscitation and care.

(7) The placenta and all membranes are manually removed from the uterus.

(8) The uterine edges are grasped with Pennington clamps and a layered closure begun. A continuous suture of chromic gut number 0 or number 2-0 is placed through the deep myometrium (and possibly endometrium). A second layer of similar

sutures is placed in the superior myometrium and serosa. A sponge count is taken as the uterine cavity is closed.

(9) A tubal ligation may be done at this time.

(10) The bladder flap of peritoneum is sutured to the visceral layer with a continuous chromic gut suture number 2-0 swaged to a taper-point needle.

(11) The fascia and skin are closed as for laparotomy. A pressure dressing is applied to the abdomen and a pad to the perineum.

Continue with Exercises

EXERCISES, LESSON 2

INSTRUCTIONS: The following exercises are to be answered by marking the lettered response that best answers the question or best completes the incomplete statement or by writing the correct word or phrase in the space provided.

After you have completed all the exercises turn to "Solutions to Exercises" at the end of the lesson and check your answers.

1. The ovaries produce ova and _____.
 - a. Urine.
 - b. Hormones.
 - c. Blood sugar.
 - d. White blood cells.

2. The uterus is located behind the _____ and in front of the rectum.
 - a. Bladder.
 - b. Isthmus.
 - c. Rectum.
 - d. Ovary.

3. The true pelvis is situated _____ the arcuate line.
 - a. Above.
 - b. Below.
 - c. Medial to.
 - d. Lateral to.

4. An operation for urinary stress incontinence frequently involves repair of the muscle.
 - a. Gluteal.
 - b. Hypomeric.
 - c. Pubococcygeal.
 - d. Crampton's.

5. During the lymphadenectomy portion of radical vulvectomy _____ ligation is performed.
 - a. Ovarian artery.
 - b. Saphenous vein.
 - c. Common iliac vein.
 - d. Deep femoral artery.

6. Vaginal plastic repair involves reconstruction of:
 - a. Pelvic floor.
 - b. Vaginal walls.
 - c. Muscles of rectum and uretha.
 - d. Muscles of bladder and perineum.
 - e. All of the above.

7. Incontinence may result from:
 - a. Vaginitis.
 - b. Gastritis.
 - c. Uremic acidosis.
 - d. Urethrovaginal fistula.

8. Urinary drainage systems are frequently used during vaginal surgery.
 - a. True.
 - b. False.

9. An older woman suffering from deep cervical laceration uncomplicated by infection may have an operation called:
 - a. Trachelorrhaphy.
 - b. Strabotomy.
 - c. Barsky's.
 - d. Kock's.

10. Part of the portio vaginalis is removed in which of the following procedures?
 - a. Vulvectomy.
 - b. Lymphadenectomy.
 - c. Amputation of the cervix.
 - d. Vesicourethral suspension.

11. A scalpel conization may be indicated when there is a positive reading from what test?
 - a. Cervical biopsy.
 - b. Boveri's test.
 - c. Orcinol test.
 - d. Pap smear.

12. Radioactive materials such as radium or cobalt are often used in the cervix for the local treatment of:
 - a. Cancer.
 - b. Tuberculosis.
 - c. Benign tumors.
 - d. Cervical infection.

13. Vaginal hysterectomy means that the vagina is removed.
 - a. True.
 - b. False.

14. A way of viewing the various pelvic structures without extensive abdominal surgery is through the use of a(n):
 - a. Cystoscope.
 - b. Culdoscope.
 - c. Bronchoscope.
 - d. Uterine cannula.

15. The procedure in which the vagina is sutured shut is called the colpocleisis or _____ operation.
- a. Treve.
 - b. Le Fort.
 - c. Rastelli.
 - d. Burkhandt.
16. One name for the endoscopic visualization of the peritoneal cavity through the anterior abdominal wall is:
- a. Cystoscopy.
 - b. Proctoscopy.
 - c. Laparoscopy.
 - d. Bronchoscopy.
17. For a single hysterectomy, a _____ incision is usually done.
- a. Pfannenstiel.
 - b. Metzenbaum.
 - c. Bermann.
 - d. Wilde.
18. Even if an ovarian tumor is benign, the entire ovary is removed.
- a. True.
 - b. False.

19. In subtotal hysterectomy, the _____ is left in place.
- Cervix.
 - Uterus.
 - Round ligament.
 - Fallopian tubes.
20. Conservative surgery for pelvic inflammation or endometriosis may involve:
- Opening arteries.
 - Shortening ligaments.
 - Subtotal hysterectomy.
 - Binding uterus down to the cul-de-sac.
21. Great care must be exercised in the removal of a dermoid ovarian cysts because:
- They are cancerous.
 - Their contents are irritating.
 - Hemorrhage is a special danger.
 - Postoperative care is especially difficult.
22. When an operation for sterilization is indicated, it is usually done during a cesarean delivery or _____ days after a normal delivery.
- 10 to 12.
 - 6 to 10.
 - 3 to 6.
 - 1 to 3.

Check Your Answers on Next Page

SOLUTIONS TO EXERCISES, LESSON 2

1. b (para 2-6b)
2. a (para 2-4a)
3. b (para 2-2a)
4. c (para 2-18a(1))
5. b (para 2-14c(1)(f))
6. e (para 2-15a(1))
7. d (para 2-16a(4))
8. a (para 2-12d)
9. a (para 2-21a)
10. c (para 2-23a)
11. d (para 2-27a(2))
12. a (para 2-28a)
13. b (para 2-34a)
14. b (para 2-29a)
15. b (para 2-33)
16. c (para 2-35a)
17. a (para 2-36c(2))
18. b (para 2-40)

19. a (para 2-37)
20. b (para 2-39)
21. b (para 2-40b(2))
22. d (para 2-43a(2))

End of Lesson 2

LESSON ASSIGNMENT

LESSON 3

Procedures in Genitourinary Surgery

TEXT ASSIGNMENT

Paragraphs 3-1 through 3-44

LESSON OBJECTIVES

After completing this lesson, you should be able:

- 3-1. Identify terms and definitions that are related to genitourinary surgery.
- 3-2. Identify the anatomy and physiology of the genitourinary organs.
- 3-3. Identify general considerations in genitourinary surgery.
- 3-4. Identify operations on the kidney, ureter, and adrenal glands.
- 3-5. Identify operations on the bladder and prostate.
- 3-6. Identify operations on the scrotum, penis, and urethra.

SUGGESTION

After completing the assignment, complete the exercises at the end of this lesson. These exercises will help you to achieve the lesson objectives.

LESSON 3

PROCEDURES IN GENITOURINARY SURGERY

Section I. ANATOMY AND PHYSIOLOGY OF THE GENITOURINARY ORGANS

3-1. INTRODUCTION

The urinary organs in the male or female include two kidneys that excrete urine, two ureters that convey urine from the kidneys to the bladder, which in turn serves as a reservoir for the reception of urine, and a urethra through which the urine is discharged from the body. In the male, the reproductive system consists of the testes, vas deferens, seminal vesicles, penis, urethra, prostate, and bulbourethral glands. These organs have a direct or indirect function in the process of procreation. The reproductive system in the female has been discussed in lesson 2.

3-2. THE KIDNEYS

a. The kidneys are situated in the retroperitoneal space on the muscles of the posterior abdominal wall, one on each side of the vertebral column at the level of the twelfth thoracic to third lumbar vertebrae. Their position may vary slightly, but usually the right kidney lies lower than the left because of the space occupied by the liver. The placement of the kidneys is shown, in figure 3-1.

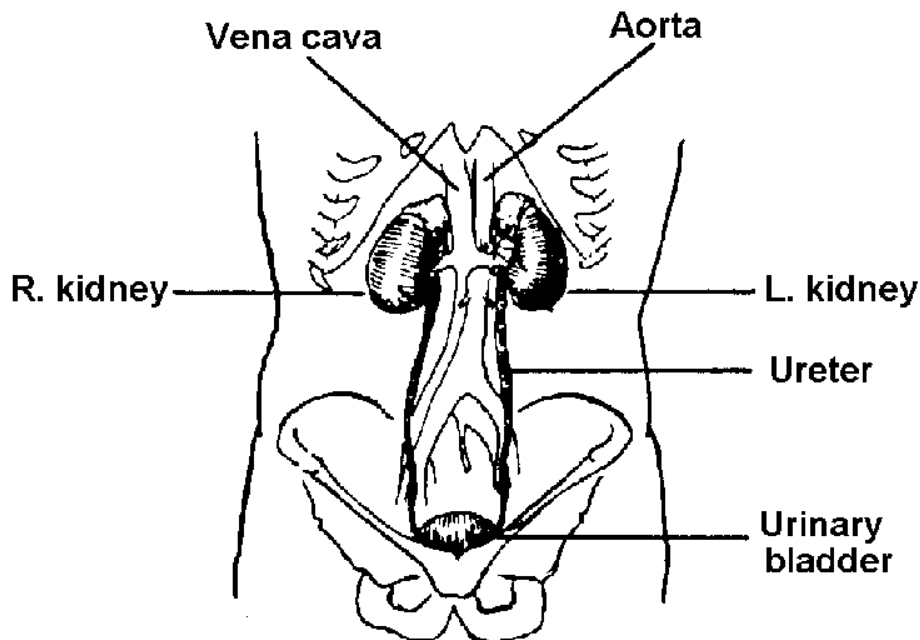


Figure 3-1. Male urinary organs in relation to other structures.

b. Each kidney is surrounded by a mass of fatty and loose areolar tissue, known as perirenal fat. Each kidney and fat capsule is surrounded by a sheath of fibrous tissue called Gerota's capsule, or renal fascia, which is connected to the fibrous tunic of the kidney by trabeculae. The kidneys are held in place by the renal fascia, which connects with the fascia of the quadratus lumborum muscle of the loins, the psoas major muscles, and the diaphragm.

c. On the medial side of each kidney there is a concave notch (called the hilum) through which the ureter, arteries, and veins enter and leave and where the renal pelvis is found.

d. The substance of the kidney (see figures 3-2 and 3-3) consists of an outer portion called the cortex, and an inner portion, called the medulla. The cortex contains the glomeruli (see figures 3-3 and 3-4) and the functioning tubules. The medulla contains many collecting tubules and papillary ducts. Each of the latter empties on a papilla within a minor calyx. Several of these join to form a major calyx. These unite to form--and therefore in turn empty into--the renal pelvis, consisting of smooth muscles lined with epithelium. The funnel-shaped renal pelvis of each kidney is continuous with the ureter below.

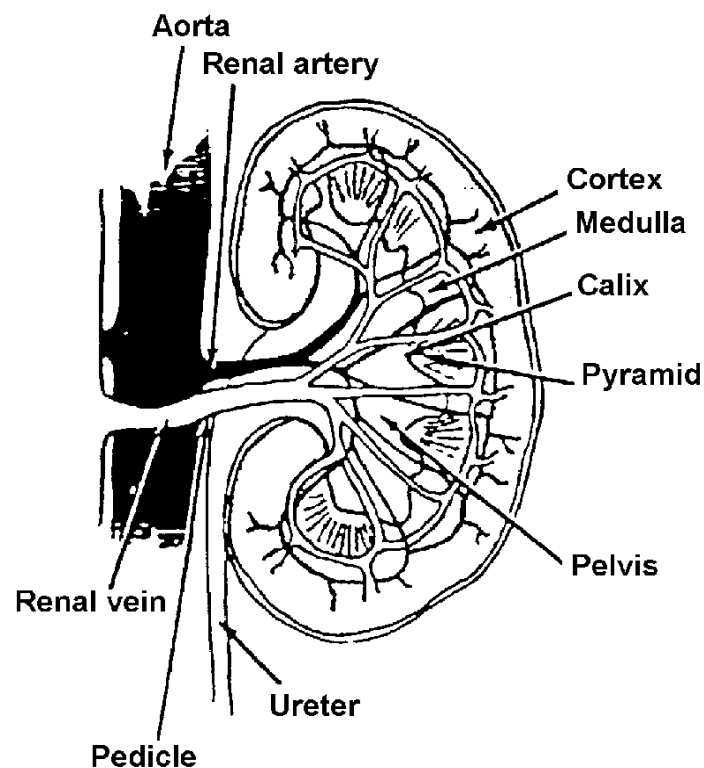


Figure 3-2. The kidney.

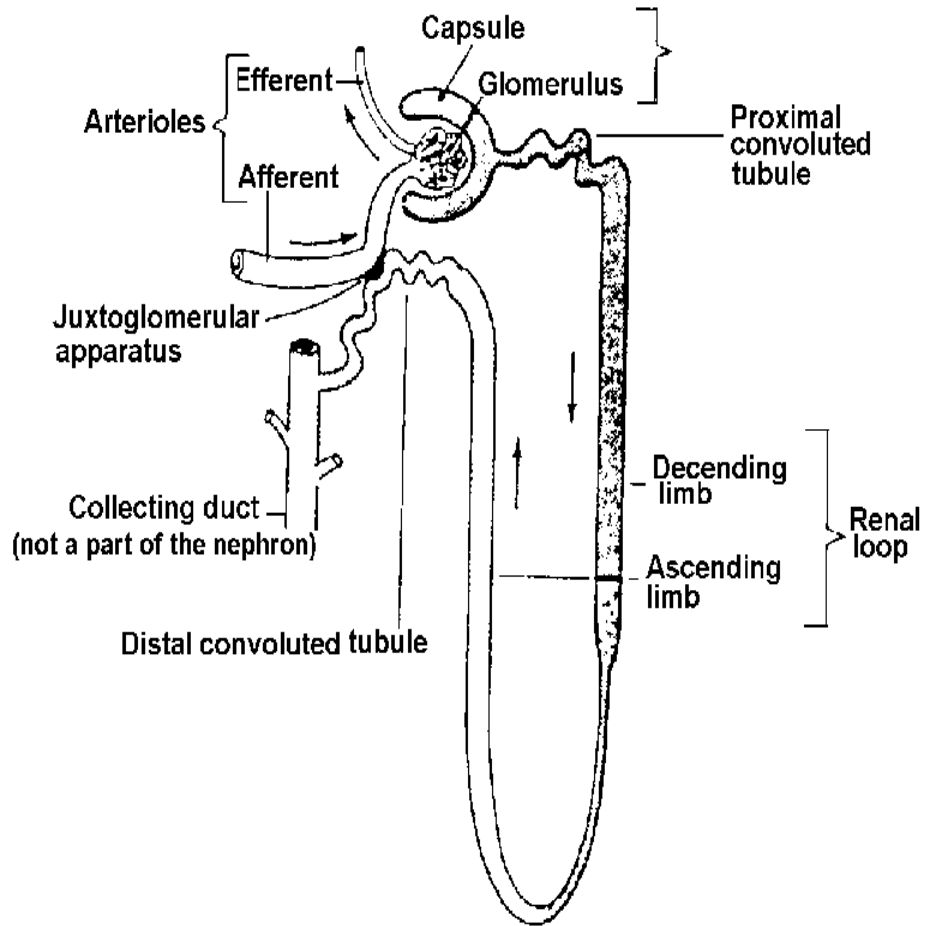


Figure 3-3. A "typical" nephron.

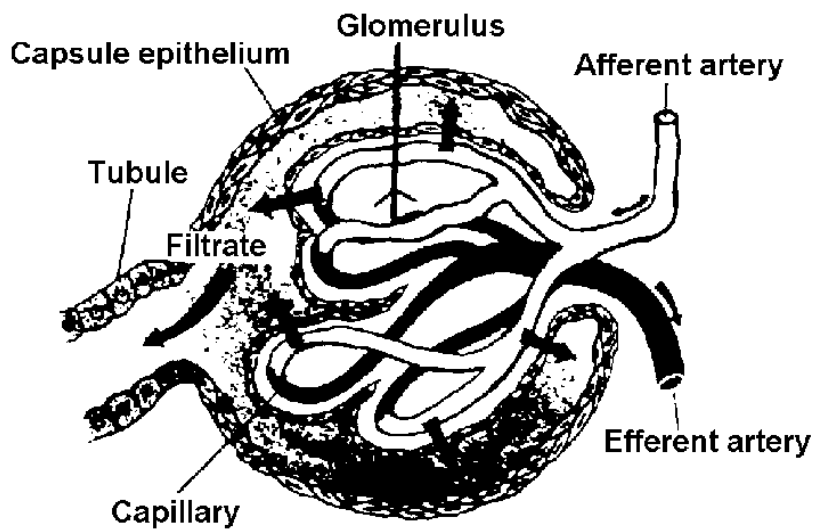


Figure 3-4. Renal corpuscle.

e. The kidneys are very vascular because one-fourth of the entire volume of blood passes through them at any one time. They receive their blood supply through the renal arteries that originate from the aorta. Each renal artery divides into several branches called afferent vessels.

f. The lymphatic supply for the most part drains into the lymph nodes that are located between the renal vessels and the aorta, and it accompanies the venous drainage.

g. The nerves of the autonomic (involuntary nervous) system carry pain sensations from the urinary organs. The nerve supply to the kidney comes from the lumbar sympathetic trunk and from the vagus nerves. Removal of the nervous pathways disrupts the ability to feel pain without impairing kidney function.

3-3. THE URETERS

Each ureter is a continuation of the cuplike calyces and renal pelvis. The ureter extends from the renal pelvis to the base of the bladder as a cylindrical tube. Each tube is about 25 to 30 cm long (10 to 12 inches) and 4 to 5 mm (1/5 inch) in diameter. Each consists of three layers: an outer adventitial layer, a muscular layer, and an inner epithelial lining. See figure 3-5.

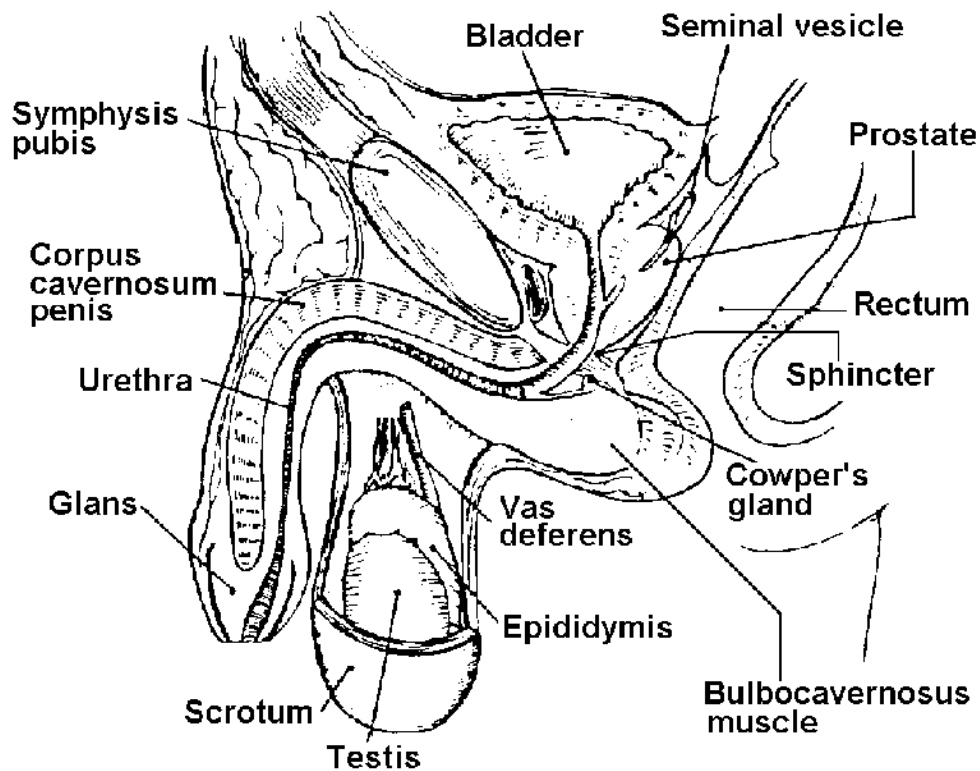


Figure 3-5. Genitourinary system (male).

3-4. URINARY BLADDER

a. The urinary bladder (see figure 3-5) is a musculomembranous sac situated in the pelvic cavity behind and below the symphysis pubis, in front of the rectum, and above the prostate gland in the male. The bladder lies in front of the neck of the uterus and the anterior wall of the vagina in the female. When the bladder becomes full and distended, it begins to ascend above the symphysis pubis, pushes its peritoneal covering ahead of it, and partially becomes an abdominal structure.

b. The bladder is connected to the pelvic wall by fascial attachments that extend from the back of the pubic bones to the front of the bladder. Other muscular fibers also pass from the base of the bladder to the sides of the rectum.

c. The bladder consists of a thick muscular wall with outer adventitial and inner mucosal layers. In addition, a peritoneal layer partially covers and is attached to the bladder dome. The blood supply of the bladder is derived from branches of the anterior trunk of the hypogastric artery.

d. As a result of the peristaltic muscular contraction of the renal pelvis and ureter, the urine is actively propelled from the kidney to the bladder and expressed from the ureteral orifice.

e. The size, position, and relation of the bladder to the intestines, rectum, and reproductive organs vary according to the amount of fluid it contains. The process of emptying the bladder appears to be initiated by nerve cells from the sacral divisions of the autonomic nervous system. These sacral reflex centers are controlled by higher voluntary centers in the brain. Stimulation from the sacral centers results in contraction of the bladder muscle and relaxation of the bladder outlet sphincters. Muscle tone maintains closure of the sphincters when the bladder is at rest.

3-5. MALE URETHRA

The male urethra (see figure 3-5) is a tube about 20 cm (8 inches) in length that forms an S curve. It is the terminal portion of both the urinary and reproductive tracts. The male urethra has three divisions: the prostatic urethra, which passes through the prostate gland, the membranous urethra, which contains the external sphincter of the bladder, and the remainder, called the bulbous urethra. The male urethra is composed of mucous membrane that is continuous with that of the bladder and merges with the submucous tissue, which in turn connects the urethra with other structures that it traverses.

3-6. FEMALE URETHRA

The female urethra (see figure 2-2 of Lesson 2) is a narrow membranous hollow tube about 4 cm (1/2 inches) in length and 6 mm (1/4 inch) in diameter. When it is not in use, however, its walls collapse. This structure lies behind and beneath the

symphysis pubis and anterior of the vagina. The external urethral orifice (urinary meatus) lies anterior to the vaginal opening and posterior to the clitoris.

3-7. MALE REPRODUCTIVE ORGANS

a. The male reproductive organs (see figure 3-5) include the two testes, epididymides, seminal ducts (vas deferens), seminal vesicles, Cowper's glands, and ejaculatory ducts, as well as the single reproductive organs of the prostate, penis, and urethra. The scrotum is located behind the base of the penis and in front of the anus. This loose sac contains and supports the testes, the epididymides, and some of the spermatic cord. The two sides of the scrotum are separated from each other by a median raphe. Within the scrotum there are two cavities or sacs that are lined with smooth and glistening tissue, known as the tunica vaginalis. Normally, a small amount of clear fluid is contained in the tunica vaginalis. The condition known as hydrocele denotes an abnormal accumulation of this fluid.

b. The testes manufacture the spermatozoa and also contain a specialized cell (Leydig) that produces the male hormone. Each testis consists of many tubules, in which the sperm are formed, surrounded by a dense capsule of connective tissue. The tubules coalesce and continue into the adjacent epididymis where the sperm mature and are stored.

c. The epididymis is a long narrow organ that lies along the posterior border of each testis. It connects the testis with the seminal duct. The vas deferens (ductus deferens, or seminal duct) is a distal continuation of the epididymis. Each is the excretory duct of the testis and conveys the sperm from the epididymis to the seminal vesicle.

d. The vas deferens lies within the spermatic cord in the inguinal region. The spermatic cord also contains the veins, arteries, lymphatics, nerves, and surrounding connective tissue (cremaster muscle) that give support to the testes.

e. The seminal vesicles are structures that unite with the vas deferens on either side. The terminal portion of each vas deferens is called the ejaculatory duct, which passes between the lobes of the prostate gland and opens into the prostatic urethra.

f. The prostate gland is an accessory sex organ. It lies just below the bladder in front of the rectum and surrounds the prostatic portion of the urethra. The entire prostate gland, which consists of five lobes, is surrounded by a fibrous capsule, through which the ejaculatory ducts enter to pass through the gland. Behind the prostatic capsule, there is a fibrous sheath that separates the prostate gland and the seminal vesicles from the rectum. The lobes of the gland secrete a highly alkaline fluid that dilutes the testicular secretion as it comes from the ejaculatory ducts. The prostate gland receives its blood supply from the internal pudendal, inferior vesical, and hemorrhoidal arteries.

g. Two small bodies called Cowper's glands are situated on either side of the membranous portion of the urethra inferior to the prostate. Each gland via its duct empties mucous secretions into the urethra.

h. The penis is a pendulous organ suspended by the fascial attachments of the pubis arch and supported by the suspensory ligaments. The penis contains three distinct vascular sponge-like bodies: the two upper bodies are called the right and left corpus cavernosum and the lower body, the corpus spongiosum urethras. The tissue contains a network of vascular channels that fill with blood on erection. At the distal end of the penis, the skin is doubly folded to form the so-called prepuce, or foreskin, which serves as a covering for the glans penis. The glans penis contains the urethral orifice.

3-8. ADRENAL GLANDS

The adrenal glands lie retroperitoneally beneath the diaphragm at the medial aspect of the superior pole of each kidney. On the right side, the gland is adjacent to the inferior vena cava; on the left side, the gland is posterior to the stomach and pancreas. Each adrenal gland has a medulla, which secretes adrenaline, and a cortex which secretes steroids and other hormones. The glands are freely supplied with arterial branches from the phrenic and renal arteries and from the aorta. The venous drainage is accomplished on the right by the inferior vena cava; on the left, by the left renal vein.

Section II. GENERAL CONSIDERATIONS IN GENITOURINARY SURGERY

3-9. INTRODUCTION

a. Operating room personnel must have a good understanding of the procedure that is planned in order to properly prepare the patient, room, equipment, and supplies. Safety is the prime consideration since the patient is positioned in a lateral, prone, or lithotomy position. These positions are frequently exaggerated to give better access to the organs involved, as for a radical operation on the prostate and bladder. Care must be taken to avoid displacement of the joints in lithotomy as the anesthetized patient is positioned. This is especially true in aged or debilitated patients.

b. In positioning a patient laterally for kidney surgery, the spine is extended to give more access to the retroperitoneal space. This patient should have padding and stabilizing support from rubber-covered pillows, sandbags, and straps. If the electrocautery unit is to be used, care must also be taken to see that no part of the patient touches metal equipment other than the indifferent electrode plate attached to the cautery unit.

c. In some procedures involving stones of the kidneys or ureters, it may be necessary to make X-ray examinations during the procedure. A cassette holder must be placed under the patient who is in the supine, prone, or lithotomy position. The patient positioned laterally will be X-rayed by a cassette held in a sterile wrap.

3-10. ASEPTIC TECHNIQUES AND SAFETY MEASURES

- a. Aseptic techniques in skin preparation and draping must be carefully maintained. Difficulty may be encountered in cleansing and preparing the perineal area. Spray apparatus may be preferred to gauze sponges on forceps for application of antiseptic in perineal skin preparations.
- b. Draping procedures for laparotomy are described and illustrated in Subcourse MD0927.
- c. The disposable O'Connor perineal drape with finger cot may be used.
- d. Transurethral passage of instruments and catheters requires meticulous aseptic technique to prevent retrograde infections of the urinary system. The use of transurethral instruments is facilitated by darkening the room. There should be provision for proper adjustments in lighting.
- e. Electrosurgical units and battery cords are frequent adjuncts in urological surgery. The staff must be familiar with their use and with the precautions necessary to prevent fire, explosion, or burns.

3-11. DISTENTION OF THE BLADDER

When the bladder is to be opened or manipulated, it is frequently distended with irrigating fluid prior to surgery. Provision must be made in positioning and draping of the patient and in instrument selection for filling and draining the bladder prior to or during the course of the operation.

3-12. DRAINAGE TUBES AND CATHETERS

- a. Ureteral catheterization may also precede radical operations. Preoperative preparations of the patient and cystoscopy instruments with catheterizing telescopes are needed.
- b. Whenever the urinary tract is opened, there is the danger of leakage of urine. All such wounds require careful drainage. Drainage tubes in the urinary tract must be kept open at all times and the surgeon should be notified immediately if there is no drainage. The tube or catheter used to drain the bladder suprapubically must be stiff enough to prevent collapse. An angulated tube or catheter may be useful in preventing kinking if bulky dressings are used. The catheters or tubes should be tested for patency, flushed and suctioned prior to use. Modern vacuum drainage collectors (of the Hemovac type) have been successful in maintaining drainage and keeping wounds dry.
- c. Ureterostomy and nephrostomy tubes must be carefully identified, fixed in position, and guarded to prevent dislodgment or obstruction. There are various types of catheters available for specific situations. Catheters are used for diagnostic purposes

and to explore the urethra for stenosis, discover residual urine in the bladder, and introduce contrast medium into the bladder.

d. Filiform tips and followers are used to dilate narrow strictures. Graduated woven ureteral catheters are used to introduce radiopaque material or obtain a sterile urine specimen from the renal pelvis and to help determine renal function.

e. The olive-tipped bougies are used to calibrate the urethra. The silk woven catheter may be used to manipulate past enlarged prostatic lobes. In some cases, a catheter stylet is used to insert a catheter. The catheter should be lubricated before the stylet is inserted. The catheter is drawn taut over the stylet so that its tip cannot become dislodged. Catheters with inflatable balloons are used for drainage and for pressure to help control bleeding.

Section III. OPERATIONS ON THE KIDNEY, URETER, AND ADRENAL GLANDS

3-13. GENERAL CONSIDERATIONS

a. Stones, infections, and tumors are the most common causes of urinary tract obstruction necessitating operations to prevent renal destruction or failure. Obstruction may also be due to malformations of the urinary tract.

b. Although the causes of kidney stones are obscure, certain conditions such as obstruction, stasis, or body chemistry predispose to their formation. Stones may form from various elements: calcium oxalate, calcium phosphate, magnesium ammonium phosphate, uric acid, and calcium carbonate, or combinations of these substances may be found. All stones removed at operation are usually subjected to chemical analysis. Stones obtained as surgical specimens are best submitted in a dry jar. Fixative agents such as Formalin^R can obscure the results of the analysis.

c. Stones in the renal pelvis may drop down into the opening of the ureter (the uretero-pelvic junction) and occlude it, or they may pass into the ureter and lodge at the ureterovesical junction or where the ureter passes into the bony pelvis at the level of the iliac crest. A stone may lodge in a renal calyx and continue to enlarge, eventually filling the entire calyx or renal pelvis (staghorn stone).

d. Hydroureter, hydronephrosis, and fibrosis with destruction of the renal parenchyma can result from unrelieved obstruction.

3-14. NEPHRECTOMY

a. **General.** This operation involves the removal of the kidney. It is done to treat some congenital unilateral abnormalities causing renal obstruction or severe hydronephrosis, tumor of the kidney, a severely injured kidney, renal tuberculosis, calculous pyelonephrosis, and sometimes cortical abscess.

b. **Patient Preparation.** The position of the patient on the operating table will depend on the type of lesion, the position of the kidney, and the surgical approach selected. The most common position for kidney operations is the lateral when a lumbar, transpleural, or extra-pleural transthoracic approach is to be used. A supine or a modified Trendelenburg position is employed when an abdominal approach is to be used.

c. **Approaches to the Kidney.**

(1) Lumbar or simple flank incision. This incision begins at the costovertebral angle and parallels the twelfth rib. It extends, forward and downward between the iliac crest and the thorax.

(2) Nagamatsu incision. This is a modification of the simple flank incision and is made over the eleventh and twelfth ribs, removing a section of each.

(3) Thoracoabdominal incision. The tenth and eleventh ribs are removed, and the chest cavity is opened, collapsing the lung. Rib spreaders and approximators and chest drainage are required. When the lumbar, Nagamatsu, or thoracoabdominal approach is used, the patient is placed in a lateral position.

(4) Transperitoneal and retroperitoneal incisions. The patient is placed in a supine position. A vertical incision is made in the epigastric and umbilical region on the affected side. This approach is used for a large kidney tumor or when the kidney and ureter are extensively involved in the surgery.

d. **Operative Approach (Lumbar Approach).**

(1) The incision is carried through the skin, fat, and fascia. Bleeding vessels are clamped with hemostats and ligated.

(2) The external oblique, the latissimus dorsi, and the internal oblique muscles are exposed. The required portions of the dorsi, external oblique, posterior inferior serratus, and internal oblique muscles are split or divided and retracted with a dull rake or Richardson right-angled retractors. Bleeding is controlled. The transversalis fascia is cut with scissors. Then the iliohypogastric and ilioinguinal nerves are identified and retracted. The sacrospinal muscle is retracted. The deep lumbar fascia is separated. The quadratus lumborum muscle may be divided.

(3) The pleura, peritoneum, and twelfth thoracic artery and nerve are identified and retracted. Laparotomy pads and Deaver retractors are placed to protect the adjacent structure and afford exposure.

(4) If necessary, a rib or ribs (twelfth, eleventh, or tenth) may be resected to give access to the kidney. The periosteum is stripped with an Alexander costal periosteotome and Doyen rib raspatory.

(5) A scalpel and heavy scissors may be used to cut through the lumbocostal ligaments. The rib is grasped with an ochsner clamp and cut with rib shears, removing the portion necessary to expose the kidney.

(6) Retractors and pads are placed. Gerota's fascia, the perirenal capsule, is grasped with long tissue forceps and incised with a scalpel. The incision is extended, using dissecting scissors, and the kidney and perirenal fat are exposed. The kidney is dissected free, using sharp and blunt dissection with long tissue forceps, scissors, and sponges on forceps. Crile hemostats are used on bleeding vessels.

(7) The ureter is identified, separated from its adjacent structures, and retracted. Holding forceps such as long Babcock or long Allis clamps may be used, or a length of Penrose tubing may be passed around the ureter to retain and retract it. The ureter is occluded by double clamping and then divided and ligated (see figures 3-6 **A** and **B**).

(8) The kidney pedicle containing the major blood vessels is isolated and doubly clamped by using long kidney clamps of a size suitable to the structures. The vessels are securely ligated with heavy chromic gut and transfixed with heavy sutures on Atraumatic needles. The pedicle is severed and the kidney removed (see figures 3-6 **C** and **D**).

(9) The wound is explored for bleeding, hemostasis secured, and the cavity cleansed by irrigating, sponging, and suctioning as necessary. A drain of Penrose tubing, which may be wicked with gauze, or a drain made of heavy rubber or plastic tubing is placed if leakage of urine is likely to occur.

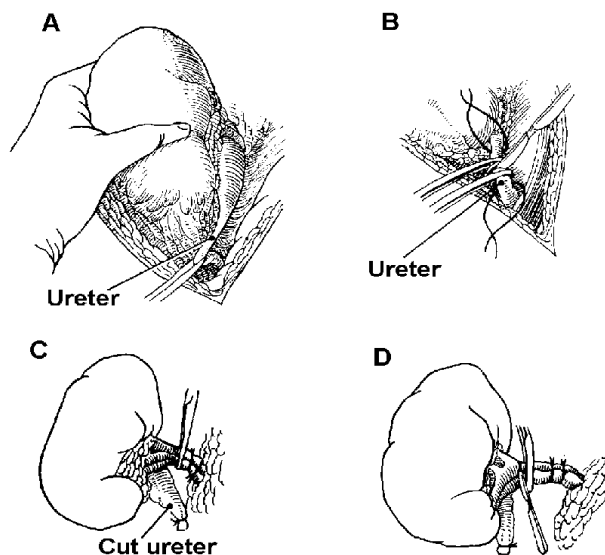


Figure 3-6. Nephrectomy.

A and **B**-Upper portion of ureter is freed, cut, and ligated. **C**-Chromic gut ligatures are placed; kidney clamps are applied between proximal ligature and kidney itself. **D**-Renal vascular pedicle is doubly ligated with suture ligatures, and the kidney is removed.

(10) The fascia and muscles are closed in layers with interrupted chromic sutures. If necessary, retension sutures may be used. The skin edges are approximated with interrupted sutures of silk or wire or with skin clips.

(11) The drain is secured and the wound dressed with gauze sponges, abdominal pads, and adhesive strips.

3-15. HEMINEPHRECTOMY

a. **General.** This procedure involves the partial excision of the kidney, and is otherwise similar to nephrectomy.

b. **Operative Procedure.** This procedure is usually indicated when one pole of the kidney has been destroyed by localized disease, such as an obstructive calculus. The rest of the kidney is healthy. This condition may be the result of a kidney being formed with two collecting systems. The capsule is pushed back, and a wedge of kidney tissue is resected, which includes the diseased or damaged cortex, pelvis, and vessels. The healthy kidney tissue is sutured with gut, the capsule is replaced and a pad of fat is sutured over the line of closure. A nephropexy will probably be done also to ensure good position and drainage.

3-16. PROCEDURES FOR OPENING THE KIDNEY

a. **Definitions.**

(1) Nephrotomy is an incision into the kidney. A simple incision and drainage may be required for hydronephrosis, cyst, or perinephritic abscess.

(2) Pyelotomy is an incision into the renal pelvis.

(3) Pyelostomy is an incision into the renal pelvis to establish drainage or to permit irrigation of the renal pelvis.

(4) Pyelolithotomy is the removal of a stone or stones through the opening made in the renal pelvis.

(5) Nephrostomy is an opening into the kidney to maintain temporary or permanent drainage. A nephrostomy is used to correct an obstruction of the urinary tract, conserve and permit physiological restoration of renal tissue that has been impaired by disease, provide permanent drainage when a ureter is unable to function, treat anuria as an emergency measure, or drain a kidney during the postoperative period following a plastic repair on the kidney or renal pelvis.

(6) Nephrolithotomy and pyelonephrolithotomy are essentially the same, since one is simply an extension of the incision. This is done in order to remove a large

stone intact or to explore a calyx where a small stone or fragment has slipped. The presence of a staghorn calculus is an indication for this procedure.

b. Operative Procedure.

(1) For opening. The kidney is approached as described for nephrectomy, using the desired incision. The renal pedicle is identified; the ureter is identified and retracted as necessary. The kidney is mobilized to permit approach to the aspect desired.

(2) For pyelotomy or pyelostomy. The pelvis of the kidney is incised with a small blade. Traction sutures of number 3-0 black silk on French eye or swaged-on needles may be placed at the edges of the incision to hold it open while the pelvis and calyces are explored. In pyelostomy, the catheter is placed through the incision directly into the renal pelvis.

(3) For nephrostomy. A curved clamp or stone forceps is passed through a pyelostomy incision into the renal pelvis and then out through the substance of the renal parenchyma via a lower pole minor calyx. The tip of a Malecot or Pezzer catheter is then drawn into the renal pelvis, and the pyelotomy incision is closed. The distal end of the tube is brought out through the flank incision. Penrose drains are placed, and the incision is closed in the regular manner.

(4) For pyelolithotomy. The renal pelvis is opened, and the ureter may be probed for stones or strictures by passing a ureteral catheter and irrigating. Stones are removed. A multieyed catheter-- Pezzer, Malecot, or Foley type--is placed. The catheter is secured with sutures. A purse-string suture may be placed around the nephrostomy tube. After removal of a staghorn calculus, mattress sutures are usually tied over a pad of renal fat to support the long parenchymal incision.

(5) For closure. An incision in the renal pelvis may be closed with fine chromic-gut swaged on needles or left unclosed. The wound is drained and closed, as for nephrectomy. Reinforced absorbent dressings or special wound decompression apparatus is required for draining wounds.

3-17. NEPHROURETERECTOMY

a. **General.** This operation involves the removal of a kidney and the entire ureter that drains it. It is indicated for the presence of hydronephrosis, a hydroureter too damaged to repair, or carcinoma of the renal pelvis or ureter. This procedure usually requires two separate incisions, one in the flank and one in abdomen. Two separate instrument sets are not required, but a second skin preparation setup and set of sterile drapes are required.

b. Operative Procedure.

(1) The patient is placed in a lateral position. The kidney and upper ureter are exposed, as described for nephrectomy, freed from their supporting structures, and brought out of the wound, taking as much ureter as possible. The ureter is not cut at this time. The wound is drained and closed in layers, leaving the kidney and ureter outside the wound, and lightly dressed.

(2) Care must be taken not to contaminate the kidney, exposed ureter, and incision as the patient is repositioned in a supine manner.

(3) The abdomen is prepped, sterile drapes are applied, and an abdominal incision is made to expose the lower ureter and bladder. These structures are freed. The ureter and a small cuff from the bladder are removed.

(4) At this time, the kidney and entire ureter are gently pulled free through the flank incision.

(5) A Penrose-type drain or catheter is placed in the bladder, and it is closed with chromic suture number 2-0. The abdomen is closed in layers and both wounds are dressed with gauze sponges and abdominal pads.

3-18. RECONSTRUCTIVE OPERATIONS ON THE KIDNEY

a. General.

(1) Pyeloplasty is a revision or reconstruction of the renal pelvis. It is done to create a better anatomical relationship between the pelvis of the kidney and the ureter and to relieve pain and obstruction to the flow of urine from the kidney. It may be necessary to ligate aberrant vessels, divide fibrous bands, resect stenotic areas, or reconstruct a redundant kidney pelvis to accomplish this and prevent or relieve hydronephrosis and hydroureter.

(2) Ureteroplasty is a reconstruction of the ureter, usually at the ureteropelvic junction.

(3) A Foley-Y pyelouretero-plasty may combine correction of a redundant kidney pelvis with resection of a stenotic area of the ureter.

b. Operative Procedure.

(1) The kidney and upper ureter are exposed, as for nephrectomy (refer to paragraph 3-14), using the desired approach.

(2) The kidney pelvis and ureter are incised, trimmed, and shaped to the desired contour, using fine forceps and scissors. A caliper and a ruler may be used for

establishing more precise relationships to improve urinary drainage. Anchoring sutures or soft rubber drains may be used for traction during handling and repair. The repair is completed using fine sutures and needles, as specified by the surgeon. The technique used is designed to provide a direct funnel-shaped enlarged outlet. The Foley Y-V plasty technique may be used for this purpose. It converts a Y-shaped incision into a V-shaped one by resecting the redundant tissue between the arm and the stem of the Y. Fine, interrupted stitches are placed to make the repair. Stenotic areas of the ureter are excised as necessary and the ureter anastomosed with fine, everting stitches (ureteroureterostomy).

(3) A nephrostomy tube may be placed through a stab wound in the renal parenchyma. A splinting latex catheter 8 or 10 Fr may be placed to extend along the nephrostomy drain through the kidney pelvis and into the ureter beyond the site of the plastic repair.

(4) The incision is closed in layers and the wound dressed.

3-19. KIDNEY TRANSPLANT

a. General.

(1) This procedure involves the removal of a donor kidney by means of a nephrectomy and ureterectomy with transplant of the donor's kidney in the recipient's iliac fossa. This is done in an effort to restore kidney function and thus maintain life in a patient who is succumbing to renal failure.

(2) The patient selected for kidney transplant is usually young, well advanced in irreversible uremia, free of other significant disease or infection, and free of obstruction in the lower urinary tract.

(3) A kidney replacement may be chosen from a living donor or from a cadaver that is without disease and of the same blood group as the recipient. The ideal living donor is an identical twin, although family members or other volunteers may be selected.

(4) It is important that the time lapse between donor nephrectomy and transplantation of the organ to the recipient be kept to a minimum. In living donors, hypothermia may be used to reduce the oxygen requirements of the kidney.

b. Preparation. Two adjacent operating rooms are prepared for the surgery, and the operations on donor and recipient proceed simultaneously. On a cadaver donor, the supine position is used, and a disposable drape with a large fenestration is used to provide adequate exposure for bilateral nephrectomies. For a living donor, either the lateral or supine position may be used. The recipient lies in the supine position.

c. Donor Operation.

(1) In living donors, angiography assists in selection of the preferred donor kidney.

(2) The donor nephrectomy is done much as the procedure already described in paragraph 3-14, but the surgeon will do a delicate dissection to prevent trauma to the renal vessels and ureter.

(3) The patient may be given intravenous mannitol before the kidney is excised, and the surgeon may inject 1percent lidocaine (Xylocaine®) about the renal pedicle before its dissection to prevent vasoconstriction. The scrubbed nursing team member should have sterile iced normal saline available to cool the kidney immediately after it is removed.

(4) If the donor kidney is cooled by intraarterial perfusion, cold (15°C), sterile, lactated Ringer's solution to which heparin and procaine have been added will be introduced into the vessels by means of small polyethylene catheters under strict aseptic conditions. The sterile basins and donor kidney should be covered with a sterile drape and taken to the recipient operation by the surgeon.

d. Recipient Operation.

(1) The incisional approach is carried out.

(2) The donor kidney is placed in the contralateral iliac fossa of the patient and rotated 180 degrees so that the posterior surface is anterior in the patient. Placing the organ extraperitoneally may prevent peritonitis if an infection develops.

(3) The renal artery is anastomosed to a branch of the hypogastric artery and the renal vein to the external iliac vein.

(4) The ureter, depending on its length, may be implanted into the bladder directly by a tunneling technique, or it may be anastomosed to the recipient ureter. A cystostomy tube may be inserted into the bladder.

NOTE: Bilateral nephrectomies and splenectomy may be performed on the recipient at the time of transplant or at another time, depending on the patient's general condition and the surgeon's program of management. This is done to prevent hypertension or urinary tract infection.

3-20. RECONSTRUCTIVE OPERATIONS ON THE URETER

a. **General.** Reconstructive operations may be indicated because of a pathological condition of the urinary bladder or lower ureter that interferes with normal drainage. Conditions requiring urinary diversion or reconstruction of the urinary tract

include malignancy, cystitis, stricture, trauma, or congenital malformations such as ureteral reflux. Pelvic malignancy or an anomaly requiring removal of the bladder necessitates urinary diversion.

b. Definitions and Purposes.

(1) Ureterostomy (ureterotomy). The opening of the ureter for continued drainage from it into another part.

(2) Cutaneou-ureterostomy (anastomosis or transplant). The diversion of the flow of urine from the kidney via the ureter away from the bladder onto the skin, usually on the abdomen.

(3) Ureterectomy. The complete removal of the ureter. This procedure includes nephrectomy, as well as the excision of a cuff of the bladder.

(4) Uretero-lithotomy. An incision into the ureter and removal of a stone.

(5) Ureterou-reterostomy. The division of the ureter and reconstruction in continuity with another ureteral segment (see figure 3-7).

(6) Ureteroileostomy (ileal conduit) or ureterosigmoidostomy (anastomosis). The diversion of the ureter into a segment of the ileum or into the sigmoid colon.

(7) Ureteroneocystostomy (ureterovesical anastomosis). The division of the ureter from the urinary bladder and reimplantation of the ureter into the bladder at another site.

c. Patient Preparation. The site of incision and position of the patient will depend on the indications for surgery and the nature of the proposed reconstruction or anastomosis. The patient may be placed in a supine position for an abdominal approach or in a modified Trendelenburg position for a low abdominal or pelvic incision. The patient may also be placed in a lateral position for high ureteral stones.

d. Operative Procedure for Ureteral Anastomosis.

(1) The ureter is exposed through the desired incision. A ureteral catheter, passed retrograde, may be used to facilitate identification and isolation of the ureter. The ureter is identified and dissected free, using long forceps and scissors.

(2) The ureter is picked up with fine traction sutures, freed from the surrounding tissues, and severed at the desired level.

(3) The distal end of the ureter is ligated, and the proximal stoma is transferred to the site of anastomosis. The anastomosis is accomplished with fine dissection instruments and fine swaged-on sutures.

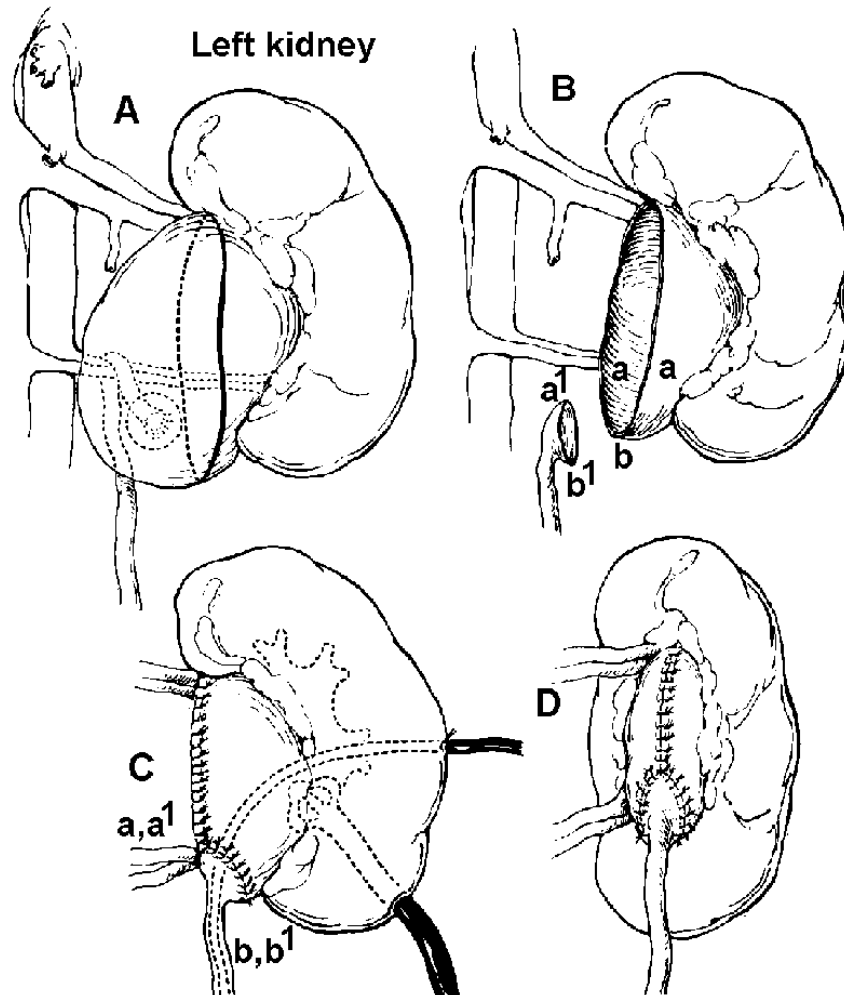


Figure 3-7. Technique of reimplantation of ureter at kidney pelvis. Correction of ureteral obstruction by aberrant vessels that cannot be divided without producing muscular renal damage.

A-Outline of proposed pelvic (ureteral) cuff and extent of redundant pelvic wall resection.

B-Ureter, with its funneled end, is brought approximated to dependent part of resected pelvic wall (a' to aa and b' to b).

C and **D**-Anastomosis completed. Nephrostomy drainage and ureteral splint may be inserted.

(4) A soft splinting catheter is usually left in place until healing has taken place and free drainage is assured.

(5) The wound is closed in layers and dressed in the routine manner.

e. Operative Procedure for Ureterolithotomy.

(1) The patient usually has a kidney, ureter, and bladder X-ray examination immediately before surgery to determine the exact location of the stone. The surgeon may also schedule a cystoscopic examination preoperatively and may attempt to manipulate the stone through the ureter.

(2) The position of the stone determines the surgical approach. A stone high in the ureter will require a flank incision, whereas one closer to the bladder will require an abdominal incision. Both of these have been described previously. The incision into the ureter is made with a small surgical blade above the stone. The Randall stone forceps will be used to locate and remove the stone. The ureter may be closed with fine chromic gut sutures number 4-0, or it may be left open and the site drained well. Either approach requires minimal routine closure.

(3) Ureterocutaneous transplant, ureterosigmoid anastomosis, and ileal segment are all urinary diversion procedures performed when the bladder no longer serves as a proper urine reservoir. The cause may be a congenital disorder (as in the neurogenic bladder), exstrophy, trauma, or tumor.

f. Operative Procedure for Ureterocutaneous Transplant (Anastomosis).

The surgical approach is the same as for a low ureterolithotomy, and the ureter is severed from the bladder. The severed ureter is passed through a stab wound in the flank and sewn to the skin with an everting suture-of number 4-0 chromic gut on an Atraumatic needle to form a stoma. The structures are handled with plastic instruments, fixation forceps, and iris scissors. A small catheter is passed into the ureter and irrigated for patency. The patient must have a urine collecting bag postoperatively.

g. Operative Procedure for Ureterosigmoid Anastomosis.

(1) The abdomen and peritoneal cavity are entered in the routine manner through a left rectus incision. A portion of the large bowel is protected with pads. Deep retractors are placed, and with long forceps and scissors the posterior peritoneum is incised.

(2) The ureters are severed close to the bladder. The ureter is brought through the posterior peritoneal incision to the sigmoid. Traction sutures and smooth tissue forceps are used to retain and handle the severed ureters.

(3) The sigmoid colon is immobilized to prevent traction and tension on the ureter by securing the former to the pelvic peritoneum at a point where the ureter falls

easily on the bowel, and a silk number 3-0 traction stitch is taken. Using a scalpel with blade number 15, an incision is made through the taenia of the sigmoid muscle layer separating it from the mucosal layer. A tunnel is created by blunt dissection.

(4) The ureter is laid on top of the mucosa, and a small-slit is made in the mucosa, using a scalpel with a number 11 blade.

(5) With fixation forceps and iris scissors, the ureter is slit to match the bowel incision. The ureter is anchored to the bowel with number 4-0 chromic ureteral sutures on Atraumatic needles. The other ureter is anastomosed in the same manner in a position slightly above the first.

(6) The posterior peritoneum is closed with fine silk sutures. Drainage is established. The abdominal wound is closed in layers.

h. Operative Procedure for Ileal Conduit.

(1) A urethral catheter is inserted to decompress the bladder, and a rectal tube is placed in the rectum. Before the incision is made, the stoma site is marked on the skin. Through a midline abdominal incision, the peritoneum is incised and the abdomen is entered in the routine manner; abdominal retractors are placed.

(2) The ureters are mobilized and brought through the retroperitoneum.

(3) The distal ileum and mesentery are inspected to identify the blood supply. A Penrose drain is passed through the mesentery midway between the two main arterial arcades adjacent to the ileum at the proximal and distal ends of the selected segment. This segment usually comprises 6 to 10 inches of the terminal ileum, a few inches from the ileocecal valve.

(4) The vessels of the mesentery are ligated. Care is exercised to preserve the ileocecal artery and adequate circulation to the isolated ileal segment. The peritoneum is incised over the proposed line of division of the mesentery. Allen or other intestinal clamps are placed across the ileum, and the bowel is divided flush with the clamps. Using gastrointestinal technique, the proximal end of the conduit is closed with a chromic layer of sutures followed by a second layer of interrupted silk sutures. The remaining ileum is reanastomosed end-to-end.

(5) The mesentery is closed with interrupted silk sutures.

(6) The closed proximal end of the conduit segment is fixed to the posterior peritoneum. The ureters are implanted in the ileal segment using plastic technique, with fine instruments and ureteral sutures of chromic number 4-0 catgut on Atraumatic needles. The peritoneum and muscle of the abdominal wall lateral to the original incision are separated by blunt dissection. The distal opening of the ileal conduit is

drawn through and sewn to the skin with fine chromic or silk sutures. The wound is drained, closed, and dressed. An ileostomy bag is placed over the stoma.

NOTE: The surgeon may do a cystectomy either before or after this procedure. In some cases, he may choose to leave the bladder rather than subject a debilitated patient to further surgery.

3-21. ADRENALECTOMY

a. **General.** This operation involves the partial or total excision of one or both adrenal glands. This procedure may be done to treat hyperfunction of the adrenals, remove tumors of the glands themselves, or treat tumors elsewhere in the body that are affected by adrenal hormonal secretions, such as carcinoma of the prostate or breast.

b. **Patient Preparation.** For unilateral adrenalectomy, the patient may be placed in the lateral kidney or supine position. More often, however, both glands are explored, and the supine position is selected.

c. Operative Procedure--Lateral Approach.

(1) An incision curving from the midline and extending from the rib cage to the iliac crest is made with the scalpel through the skin, fat, and muscle. The lumbodorsal fascia is cut to reveal the sacrospinal muscle. This muscle is detached from the ribs, using forceps and dissecting scissors.

(2) The rib is resected.

(3) An opening is made through the transverse fascia with scissors. The pleura and diaphragm are protected with wet pads, and Gerota's capsule is incised to expose the kidney and adrenal gland.

(4) The gland is dissected free, using scissors and Babcock forceps. The blood supply of the gland is identified, clamped or clipped, and divided. Bleeding vessels are ligated. To release the glands, the left adrenal vein, a branch of the left renal vein, is separated by clamping and cutting. The right adrenal vein, a tributary of the vena cava, is also divided. Fine vascular sutures may be required to repair inadvertent injury to the vena cava.

(5) When hemostasis has been assured, the wound is closed in layers--muscle, fascia, subcutaneous tissue, and skin.

d. Operative Procedure--Abdominal Approach.

(1) The abdominal wall is incised, and the peritoneal cavity is opened and explored. Bleeding vessels are clamped and ligated.

- (2) The abdominal wound is retracted, and the surrounding organs protected with laparotomy pads, using instruments and sutures as for routine laparotomy.
- (3) The retroperitoneal area near the diaphragm is opened on the left side, exposing the renal fascia.
- (4) The renal fascia is opened to reveal the left kidney and adrenal gland.
- (5) The adrenal gland is freed from the kidney by sharp and blunt dissection, clamping and ligating all bleeding vessels with silk sutures number 3-0 or vascular clips.
- (6) After all bleeding is controlled, the kidney is gently replaced in the renal fascia, and closed with interrupted chromic sutures number 0.
- (7) The peritoneum is closed over the left kidney and renal fascia.
- (8) The abdominal retractors are rearranged to give access to the peritoneum over the right kidney and adrenal gland. Care must be taken here to avoid trauma to the liver.
- (9) The right retroperitoneal space is opened to reveal the renal fascia.
- (10) The renal fascia is opened, exposing the right kidney and adrenal gland.
- (11) The adrenal gland is freed in the same manner as the left one and excised.
- (12) The right kidney is replaced in the renal fascia, which is sutured closed.
- (13) The right retroperitoneal area is closed with chromic sutures #0.
- (14) The abdomen is inspected for bleeding vessels, which are ligated.
- (15) The wound is closed in the routine laparotomy fashion.

Section IV. OPERATIONS ON THE BLADDER AND PROSTATE

3-22. OPEN OPERATIONS ON THE BLADDER

a. **General.** The urinary bladder may be opened to remedy acute retention; relieve obstruction and distention; control hemorrhage; remove stones, tumors, or foreign bodies; or repair congenital or traumatic defects. Other radical procedures are performed to treat cancer. Total cystectomy requires permanent urinary diversion.

b. Definitions.

- (1) Cystotomy. A procedure in which the bladder is cut open.
- (2) Cystolithotomy. A procedure in which the bladder is opened to remove stones.
- (3) Cystostomy. A procedure in which an opening is made into the bladder for continuous drainage.
- (4) Cystectomy (total). A procedure in which the bladder and adjacent structures are excised.

c. Patient Preparation.

(1) To facilitate identification and dissection, the bladder is usually drained of urine and filled with a sterile irrigating or antiseptic solution as a part of the preoperative preparation. Equipment and instruments for catheterization and irrigation should be prepared, in addition to the surgical setup. Irrigating solutions should be sterile, isotonic, and at body temperature.

(2) The patient lies in the supine position for most open operations of the bladder. The Trendelenburg position may be desired, since it tilts the pelvis high and offers good visualization of the pelvic organs, including the bladder. The patient may be draped with a nonabsorbent disposable skin drape and a fenestrated laparotomy sheet.

d. Sterile System for Bladder Irrigation.

(1) Each hospital has its own system for bladder irrigation. Suitable solutions should be specified by the surgeon.

(2) The system may consist of prepackaged irrigating solutions and sterile sets of connecting tubing, or it may be a flask, rubber tubing, and connector set such as the Valentine irrigator, which is prepared and sterilized by the operating room personnel as part of the instrument setup. With the Cotter system, the irrigating fluids are usually mixed and poured by the operating room personnel. Sterile pitchers or other containers for mixing and pouring will then be needed.

e. Operative Procedure (Suprapubic Cystotomy and Cystostomy).

(1) The bladder is distended preoperatively with the prescribed irrigating solution instilled via catheter. A vertical or transverse suprapubic incision is made through the skin and subcutaneous layers to the muscle using a scalpel, thumb forceps, and scissors. Bleeding vessels are controlled with hemostats and ligated. Wound

towels and retractors are placed. The rectus muscle is incised or split by blunt dissection and retracted. The prevesical fat and peritoneum are retracted upward with Deaver retractors.

(2) The top of the bladder is dissected free, using thumb forceps and Metzenbaum scissors. The wall of the bladder is grasped on either side of the midline with Allis forceps. Two traction sutures of number 0 chromic gut may be placed through the bladder wall and held with straight Halsted hemostats. The muscle of the bladder is spread by blunt dissection with the tip of a clamp or scissors until the mucosa is seen. Two Allis clamps are placed, and the bladder is incised with a sharp blade. At this point the distended bladder may be emptied via the urethral catheter, which is unclamped under the drapes by the circulating member of the team, or a suction tube may be introduced through the stab wound to remove the fluid as the bladder mucosa is incised.

(3) The bladder opening is extended with scissors. Bladder retractors are placed, and the bladder is explored for diverticula, calculi, or tumor. Removal of the pathological area or other corrective procedure is carried out and wound closure begun. A Malecot catheter may be used to drain the bladder suprapubically and a Foley retention catheter to drain through the urethra. The prevesical space may be drained with Penrose tubing.

(4) The bladder is sutured in two layers. A continuous suture of catgut is used on the mucosa and interrupted stitches of chromic catgut on the muscle layer. The abdominal muscle fascia and subcutaneous tissue are closed with catgut. Tension sutures of nylon or silver wire may be needed for some patients. A suture is placed around the cystostomy tube and affixed to the skin. The skin may be closed with silk or stainless steel wire.

(5) The wound is dressed with bulky dressings. The wound and cystostomy tube are held in place by adhesive tape strips.

3-23. TROCAR CYSTOSTOMY

a. **General.** This operation consists of opening the bladder, drainage by blind puncture using needles or trocar, and insertion of a catheter.

b. **Operative Procedure.** The skin at the site of the puncture is nicked with the scalpel, and the trocar is inserted into the bladder (see figure 3-8). The trocar obturator is withdrawn, and a catheter is passed into the bladder over the catheter guide. The cannula is withdrawn, and the catheter is sutured to the wound edges. The wound is dressed.

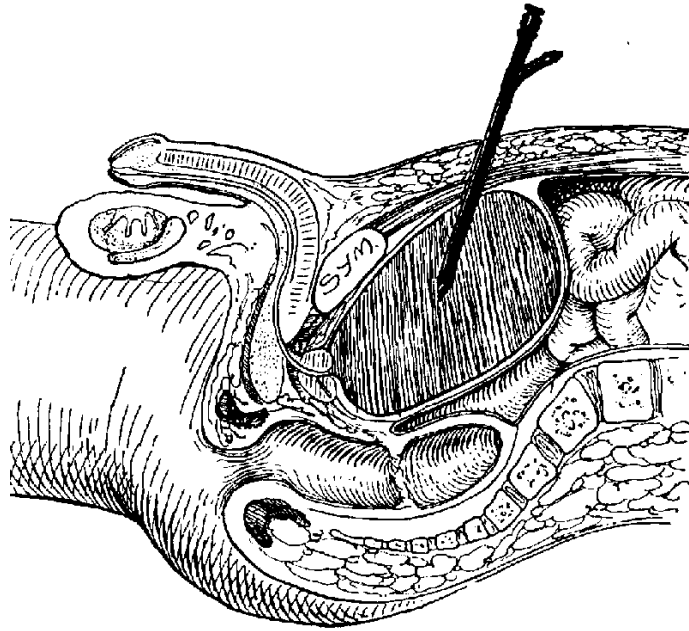


Figure 3-8. Trocar cystostomy.

3-24. PARTIAL CYSTECTOMY

a. **General.** This procedure involves the resection of a portion of the bladder having a lesion.

b. **Operative Procedure.**

(1) The bladder and lesion are exposed via suprapubic abdominal, perineal, or vaginal approach. Usually the bladder is opened suprapubically, as described in paragraph 3-22e.

(2) The ureteral orifices are identified and ureteral catheters passed.

(3) The diseased portion of the bladder is excised, using clamps and ligatures of the type required for the organs and tissues involved. Vessels are tied with number 2-0 plain gut.

(a) For vesicointestinal fistula, bowel resection with colostomy or ileostomy may be indicated. For vesicovaginal fistula, a vaginal plastic repair is done.

(b) For diverticulum, excision of the defect is done intravesically or extravesically.

(4) The incision in the bladder is sutured in two layers, as described in paragraph 3-22e(4).

(5) The bladder is drained suprapubically, as well as by an indwelling urethral catheter. Penrose drains may also be placed in the wounds.

3-25. CYSTECTOMY

a. **General.** This operation involves the total or radical excision of the urinary bladder. The extent and nature of the excision depends on the extent and nature of the pathological area. Total excision is usually carried out if the malignancy has not infiltrated the entire bladder or shown evidence of extension or distant metastasis and if the patient is in condition to withstand the procedure with hope of an appreciable period of relief. More conservative measures may be taken when the tumor is hopelessly advanced or when the pathological area is limited. If a radical procedure is to be done, combined abdominal and perineal approaches may be made.

b. Operative Procedure (Suprapubic Approach).

(1) The bladder is approached as for cystostomy.

(2) Deep retractors and laparotomy pads are used to retract the peritoneum. Long tissue forceps, stick sponges, and long scissors are used for dissection. Long hemostats or right-angled clamps are placed across the major vessels and ureters. Suture ligatures number 2-0 chromic gut are placed and the structures divided. Large pedicle or intestinal clamps are placed across the urachus and its vessels anterior to the bladder. The structures are ligated and divided by sharp dissection.

(3) In the male, the bladder is lifted up, using long Allis forceps. The peritoneum is dissected free from the bladder. The bladder is retracted to expose the vesicle neck. The bladder is dissected from the prostate and the vas deferens ligated. A large pedicle or intestinal clamp is placed across the urethra which is ligated with number 2-0 chromic sutures. The urethra is divided and the specimen removed.

(4) The seminal vesicles are removed with the bladder. Ureteral transplant is performed if not done previously.

(5) Penrose drains are placed in the suprapubic wound, which is closed in layers with #0 chromic interrupted sutures. Silver wire or nylon tension sutures may be placed. The skin is sutured with silk number 3-0 or steel wire gauge 35. The abdominal and perineal wounds are dressed.

NOTE: In the female, cystectomy will depend on the extent and nature of the pathological lesion. A vaginal approach may be used and then, via the abdominal approach, lymphadenectomy and pelvic exenteration completed.

3-26. BLADDER NECK OPERATION (Y-V-PLASTY)

a. **General.** This operation involves the plastic repair of the bladder neck. It is done to overcome contracture of the bladder neck due to primary or secondary stricture.

b. **Operative Procedure.**

(1) The bladder is approached as for cystostomy. The prevesical fat is removed, using long forceps and dissecting scissors. The vessels over the bladder neck are occluded with right-angled clamp, ligated with number 2-0 plain gut, and divided. The self-retaining bladder retractor is placed.

(2) Traction sutures of fine silk on small, fine, cutting-edge needles (cleft palate-type) are placed at the base and on either side of the urethra to start the pattern for the plastic dissection.

(3) With the aid of the traction sutures and an Allis forceps, the Y is incised through all layers as evenly as possible, using sharp-pointed scissors. Bleeding vessels in the wall of the bladder and bladder neck are ligated with plain number 2-0 gut on small Ferguson needles. The V flap is folded free, and the length of the Y arm is determined with a caliper and ruler.

(4) The apex of the V is brought to the neck of the bladder to overcome the stricture and broaden the outlet. A catheter is placed in the urethra to guide the needle and prevent the suture from penetrating the urethral mucosa. A stitch of chromic number 2-0 suture is taken through the apex of the V under the urethra to the base of the Y and tied. The closure of the plastic repair is completed with mattress suture of number 2-0 chromic on Atraumatic needles.

(5) A cystostomy tube is placed in the bladder, and the bladder and abdominal wall are closed in the usual manner for cystostomy.

3-27. VISICAL-URETHRAL SUSPENSION (MARSHALL-MARCHETTI OPERATION)

a. **General.** This operation involves the suspension of the bladder neck to the posterior surface of the pubis in the female patient for treatment of stress incontinence.

b. **Patient Preparation.** The patient is usually placed in a supine position with Trendelenburg modification, but the surgeon may prefer a frogleg modification and vaginal preparation with the insertion of a Foley catheter.

c. **Operative Procedure.**

(1) A suprapubic incision is made to expose the prevesical space of Retzius. The bladder and urethra are separated from the posterior surface of the rectus muscles and pubis by gentle, blunt dissection.

(2) Heavy chromic sutures are placed on each side of the urethra and sewn to the periosteum and cartilage on the posterior side of the pubis.

(3) The outside of the bladder wall is then sutured with chromic gut suture to the rectus muscle to further suspend the urethra and bladder.

(4) The area is drained, and the wound is closed in layers.

3-28. SUPRAPUBIC PROSTATECTOMY WITH CYSTOSTOMY

a. **General.** This procedure involves enucleation of the prostatic adenomas or hypertrophied masses via a suprapubic approach. It is required because as the male ages, the prostate gland enlarges and gradually obstructs the urethra, giving rise to symptoms of urinary obstruction. The enlargement may be benign or malignant. In benign hypertrophy, only the periurethral portion of the gland is removed. When malignancy is involved, however, total or radical prostatectomy is done. This may involve excision of the entire gland and its capsule, together with associated structures, a portion of the trigone of the bladder, and the seminal vesicles.

b. **Patient Preparation.** The patient is placed in the supine or modified Trendelenburg position, with the legs apart and the weight of the torso supported by shoulder braces. An O'Connor drape may be fanfolded at the pubis, with the penis exposed through the fenestration and the finger cot in the rectum. A towel folded lengthwise is placed over the fanfolded drape at the pubic level, and a fenestrated disposable drape is used at the site of the suprapubic incision.

c. Operative Procedure.

(1) The bladder is distended via catheter irrigation, as for cystostomy. Vasectomy is frequently done as a preliminary procedure to prevent postoperative epididymitis.

(2) The bladder is approached through the routine cystostomy incision, and the top of the bladder is dissected free, using long thumb forceps and Metzenbaum scissors.

(3) The wall of the bladder is grasped on each side of the midline with Allis forceps. Two traction sutures of chromic gut number 0 on Ferguson number 12 needles may be placed through the wall of the bladder at this point and retained on straight hemostats.

(4) The muscle layers of the bladder are spread by blunt dissection with a hemostat until the mucosa is exposed. Allis forceps are placed on either side, and the bladder is incised, using a scalpel with a number 10 blade. The opening is extended with scissors. Bladder retractors--either long-bladed loops or self-retaining type--are placed, and the bladder is explored.

(5) The surgeon places the forefinger of one hand into the rectum via the finger cot in the O'Connor drape and pushes the prostate gland forward. With the forefinger of the operating hand, the lobes of the gland are enucleated from the capsule (see figure 3-9). Bleeding is controlled with hemostats and ligatures, sutures, or electrocoagulation. Long forceps, half-length sutures, and long needle holders are required for placing sutures.

(6) Following removal of the prostate and control of bleeding, a hemostatic catheter with an inflatable bag--Foley 24 Fr with a 30-ml bag may be placed in the fossa; the balloon is adjusted under direct vision and inflated, using sterile water in a 30-ml syringe with an adapter. A hemostatic cone of Gelfoam may be used if preferred.

(7) The bladder is closed as for suprapubic cystostomy with a Malecot catheter in place. One or two wide Penrose drains may be placed in the prevesical space of Retzius. The wound is closed in layers and dressed.

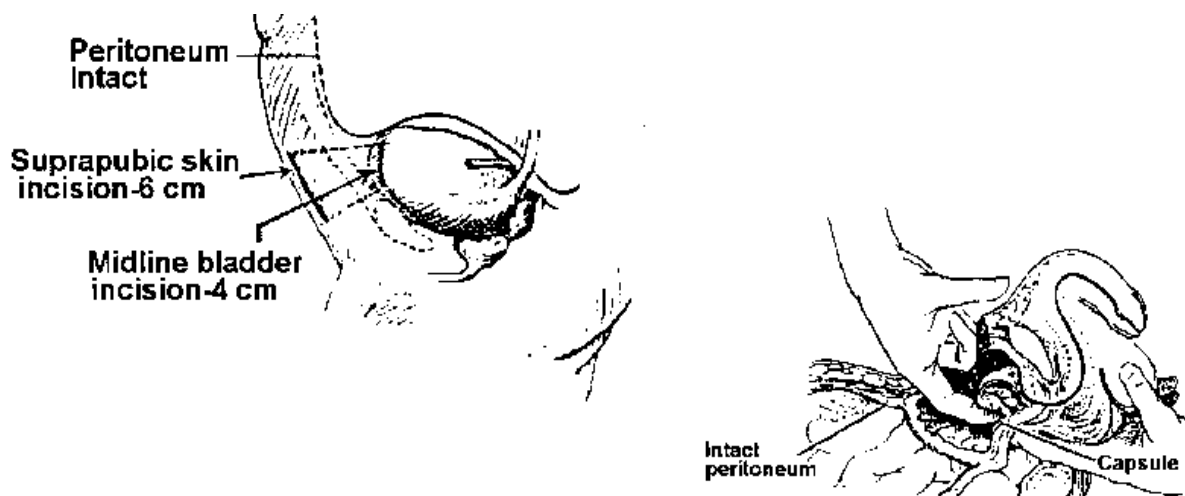


Figure 3-9. Enucleation of prostate by suprapubic approach.

3-29. RETROPUBIC PROSTATECTOMY.

a. **General.** This operation involves enucleation of the prostatic hypertrophied lobes directly through a capsular incision in the upper surface of the prostate rather than through the bladder.

b. **Operative Procedure.** See Figure 3-9.

(1) Through a vertical or transverse suprapubic incision, the abdominal wall is opened to expose the space of Retzius. The bladder is not directly opened. The precystic fat is extracted using long, smooth tissue forceps. Large vessels are ligated, using 18-inch transfixion sutures of chromic gut number 0 threaded on small Mayo needles.

(2) The prostatic capsule is incised transversely, using number 7 scalpel with a number 10 blade. The prostate is freed and enucleated, employing scissors and Allis forceps. Deep bleeding vessels are clamped with long hemostats and ligated with long plain gut number 2-0 or number 3-0 sutures with medium curved taper point Atraumatic needles.

(3) A wedge excision of the posterior bladder neck is made, using long Allis forceps, a long scalpel, and scissors. A wedge of tissue may be sutured over the defect in the bladder neck after removal of the prostate. In radical prostatectomy, a V-shaped portion of the bladder mucosa may be sutured over the defect in the bladder neck.

(4) A multieyed Robinson or Foley retention catheter is placed via the urethra. A Malecot cystostomy tube may be placed in the bladder if the surgeon desires.

(5) The incision in the prostatic capsule is closed with a continuous suture of chromic gut number 0. Penrose drains are placed in the retropubic space, the abdominal incision is closed in layers, and the wound is dressed.

3-30. PERINEAL PROSTATECTOMY

a. **General.** Either enucleation of adenomas or radical prostatectomy may be carried out through a perineal exposure.

b. **Patient Preparation.** The patient is placed on the operating table in an extreme lithotomy position. The buttocks are elevated on pads sufficient to tilt the pelvis and flatten the perineum on the vertical plane. The thighs are fully flexed with the knees to the chest and the feet are supported in stirrups. The arms are extended on armboards and shoulder braces applied with the usual precautions. Measures must be taken to reduce strain on the muscles and nerves of the back and legs and also prevent respiratory embarrassment from compression of the abdomen and chest. Draping is with an O'Connor drape and perineal sheet.

c. **Operative Procedure.**

(1) Through a curved incision made just above the anal margin, the skin, fat, and subcutaneous fascia are divided. Straight hemostats are used for bleeding vessels in the superficial tissues and curved hemostats for deeper tissues. The tissue on either side of the central tendon is dissected, using Metzenbaun scissors and forceps. McBurney retractors followed by Young bifurcated prostatectomy retractors are placed as dissection progresses. The levator ani muscles are exposed and retracted.

(2) The gland is exposed and enucleated. The surgeon manipulates the gland with a finger in the rectum via the O'Connor drape finger cot or with the hand protected by a second glove.

(3) Bleeding is controlled with sutures and electrocautery. A multieyed Robinson or Foley retention catheter is inserted into the urethra. In radical prostatectomy, the bladder neck is approximated to the urethra to cover the defect of the excision.

(4) A Penrose drain is placed in the wound. The wound is closed in layers with chromic number 0 gut sutures swaged on medium Ferguson number 14 needles. The skin edges are approximated with interrupted sutures on straight needles.

Section V. OPERATIONS ON THE SCROTUM, PENIS, AND URETHRA

3-31. HYDROCELECTOMY

a. **General.** This operation (see figure 3-10) involves the excision of the tunica vaginalis of the testis in order to remove a hydrocele. This is abnormal accumulation of fluid within the scrotum around the capsule of the testis and within the tunica vaginalism. Excessive secretion or accumulation may be due to infection or trauma.

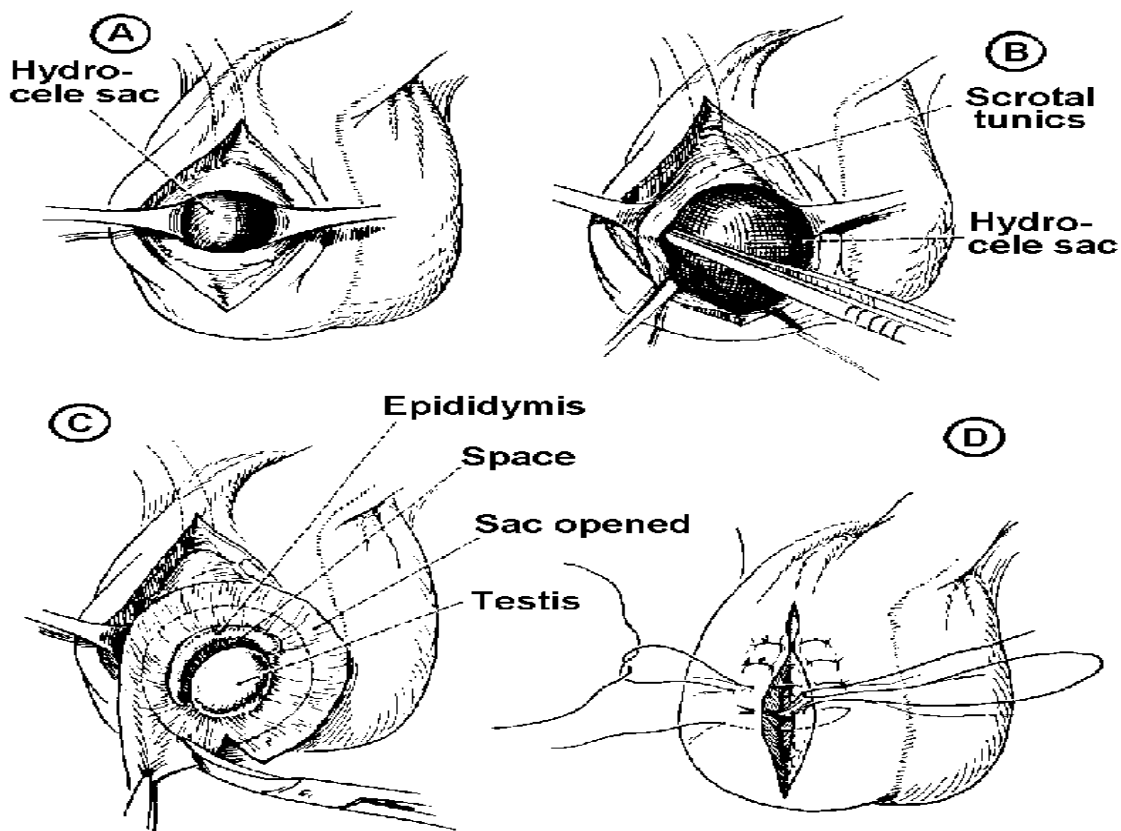


Figure 3-10. Hydrocelectomy.

A-Incision through anterior scrotum, exposing hydrocele sac. Characteristic dark blue shiny appearance of tunica vaginalis (which is sac wall) is due to deep shadow within sac.

B-Hydrocele sac enucleated and removed from scrotum. It is left attached to groin by spermatic cord.

MD0928 **C**-Sac opened and excised from testis.

D-Skin edges and subcuticular tissues approximated with single mattress sutures of no. 3-0 plain catgut.

b. **Patient Preparation.** The patient is placed in supine position and draped with fenestrated sheet.

c. **Operative Procedure.**

(1) An anterolateral incision is made in the skin of the scrotum over the hydrocele mass, using a scalpel with a number 2-0 blade. Bleeding is controlled with Crile hemostats and vessels ligated with number 2-0 plain gut ligatures.

(2) Small retractors may be placed (see figure 3-10 **A**), and then the fascial layers are incised to expose the testis and tunica vaginalis. With fine scissors and forceps, the sac is delivered and dissected free (see figures 3-10 **B** and **C**). The hydrocele may be aspirated. The adherent tunica vaginalis is separated from the internal fascia layers and the sac opened. When the tunica vaginalis has been trimmed as desired, the testis is returned to the scrotal sac.

(3) A Penrose drain is placed, and the wound is closed (see figure 3-10 **D**) in layers with Atraumatic sutures plain gut number 2-0 on curved cutting needles. The wound is dressed, and a supportive sling dressing or suspensory is usually applied.

3-32. VASECTOMY

a. **General.** This operation involves the excision of a section of the vas deferens. This is done electively as a permanent method of sterilization or birth control and also prior to prostatectomy to prevent spread of infection from the urethra to the epididymis.

b. **Patient Preparation.** The patient usually lies in the dorsal supine position, although the operation can be done in the lithotomy position prior to transurethral surgery. The procedure may be done with either local or general anesthesia.

c. **Operative Procedure.**

(1) The vas is located by palpation in the upper part of the scrotum. A small incision is made in the skin over the vas (see figure 3-11 **A**).

(2) An Allis forceps is inserted to grasp the vas and bring it to the surface of the wound (see figure 3-11 **B**). The vas is denuded of surrounding tissues of the cord, and straight clamps are placed on either side of the Allis to crush the vas.

(3) The vas is cut between the clamps and a section removed (see figure 3-11 **C**). The cut ends are doubled back and ligated with silk-or cotton number 3-0.

(4) The clamps are removed, and the skin incision is closed with plain gut #3-0 on a needle. A collodion dressing and scrotal suspensory may be applied.

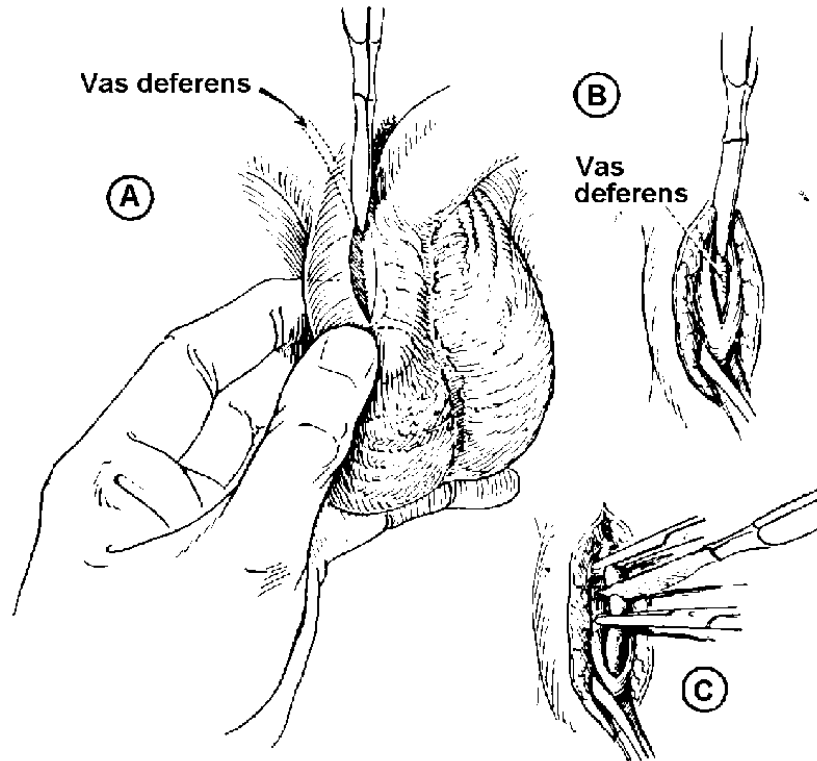


Figure 3-11. . Vasectomy (vas ligation)

A-Vas grasped between thumb in front and first and second fingers behind. Incision 2 cm long is made over vas.

B-Vas grasped with Allis clamp and incision deepened into it.

C-Vas clamped with two hemostats and incised between them.

3-33. EPIDIDYMECTOMY

a. **General.** This is the excision of the epididymis from the testis. It is rarely done but may be indicated in the treatment of persistent infection.

b. **Operative Procedure.** Incision is made over the testis in the scrotum to expose the tunica vaginalis. This is incised to expose the testis and overlying epididymis. An incision is made between the upper pole of the epididymis, which is then carefully freed from the testis. Bleeding is controlled and the wound closed with fine sutures and small drain.

3-34. SPERMATOCELECTOMY

a. **General.** This operation involves the removal of a spermatocele, which usually appears as a lobulated cystic mass within the scrotum attached to the upper

pole of the epididymis. This condition is usually caused by an obstruction of the tubular system that conveys the sperm. An epididymovasostomy may be attempted after excision of the mass to maintain the system.

b. Operative Procedure.

(1) The mass is approached through a scrotal incision as for hydrocelectomy or varicocelectomy.

(2) The structures of the testis and spermatic cord are identified, and the cyst is dissected free. Bleeding is controlled with clamps and ligatures in routine fashion.

(3) The wound is closed and dressed as for hydrocelectomy refer to paragraph 3-31c(3).

3-35. VARICOCELECTOMY

a. **General.** This procedure involves ligation and partial excision of dilated veins in the scrotum. It is done to reduce congestion of the testes and to improve spermatogenic function. The condition occurs more frequently on the left, since the vein of the left testis is connected to the renal vein and is under greater pressure. The veins of the pampiniform plexus of the spermatic cord become tortuous and engorged, causing a bag of redundant veins.

b. Operative Procedure.

(1) The incision may be made low in the inguinal canal or in the upper portion of the scrotum. The structures of the spermatic cord are identified and the vessels dissected free from the vas deferens.

(2) The abnormal vessels in the inguinal canal are clamped and ligated. The redundant portions are excised. The remaining structures are sutured to the external oblique fascia above the external inguinal ring to support the testicle.

(3) A Penrose drain may be placed. The incision is closed in layers.

3-36. ORCHIECTOMY

a. **General.** This operation involves the removal of the testis or testes. Removal of both testes is castration and renders the patient both sterile and deficient in male hormones. Because of the social implications, this operation, like vasectomy, requires particular attention to legal permission. Bilateral orchiectomy is usually performed to control carcinoma of the prostate. A unilateral orchiectomy may be

indicated because of cancer, trauma, or infection of the testis. In benign conditions, a prosthesis may be implanted for cosmetic or psychological reasons. Prostheses are usually made of silicone rubber.

b. Operative Procedure.

(1) The upper anterior surface of the scrotum is incised over the testicle. The incision is carried through the skin and fascial layers to expose the tunica vaginalis. Retractors are placed and bleeding vessels clamped and tied.

(2) The tunica vaginalis is grasped and mobilized. The spermatic cord is dissected free up to the external abdominal ring, clamped, and ligated. The testis is removed. Bleeding is controlled. A small Penrose drain may be placed in the wound. Fine sutures of plain gut number 3-0 or nylon number 4-0 are used to close the wound.

3-37. ORCHIOPEXY

a. **General.** This operation involves the suspension of the testis within the scrotum. An undescended (cryptorchid) testis is one that has failed to move properly into the normal intrascrotal position. A retractile testis is one that has descended through the inguinal canal but lies either within or superficial to the external ring. An ectopic testis is one that has descended through the canal and rests in an abnormal position (the perineal femoral area or lateral to the canal). When this operation is done on young boys, the primary goal is to obtain adequate length of the spermatic vessels and the vas to allow the testis to lie in the scrotum.

b. Operative Procedure (Transverse Inguinal Approach).

(1) An incision is made at the internal inguinal ring, the inguinal canal is opened, and the testis and cord freed. Another incision is made at the external inguinal ring and the testis is brought through the incision and into the scrotum to the proper side.

(2) The reconstruction of the muscle closure of both the internal ring and the external oblique is accomplished, using fine interrupted silk or chromic sutures.

(3) The subcutaneous tissue and skin are closed with fine sutures, as desired.

3-38. HYPOSPADIAS REPAIR

a. **General.** This surgery involves penile straightening and urethral reconstruction. Because the deformities are usually multiple, correction is usually accomplished in several stages, allowing several months to elapse between operations. The various techniques employed are for the purpose of providing a straight penis and establishing an effective urethral orifice.

b. Definitions.

(1) Hypospadias. A deformity of the penis and malformation of the urethral wall in which the urinary meatus is located on the underside of the penis, either short of its normal position at the tip of the glans or on the perineum or scrotum. This condition is often associated with chordee.

(2) Chordee. A downward bowing of the penis due to the congenital malformation of hypospadias with fibrous bands.

(3) Epispadias. A condition in which the urethral meatus is situated in an abnormal position on the upper side of the penis.

c. Operative Procedures.

(1) Chordee repair (Fraser or Nesbit technique).

(a) A transverse incision is made across the penis. Restricted fibrous tissue is dissected off the undersurface of the penis. Fine plastic scissors, a scalpel with blade number 10, and fine plastic tissue forceps are needed.

(b) With the penis held forward and the prepuce retracted, the skin is incised, and a dorsal quadrilateral flap is freed from the body of the penis.

(c) On each side, a narrow penile band of skin is divided.

(d) A transverse buttonhole is made to accommodate the head of the penis, which is threaded through it.

(e) The proximal edge of the buttonhole is sutured to the mucosa behind the corona. The preputial flap is trimmed and sutured to the raw area on the undersurface of the penis.

(f) An indwelling catheter is placed, and the wound is dressed.

(2) Urethral reconstruction.

(a) The urethra is dilated, and a Malecot catheter number 14 or number 16 Fr over a sound number 8 Fr is used to accomplish a perineal urethrostomy.

(b) On the ventral side of the penis, the Duplay flap is made to create the urethra. The edges of the flap are inverted and united over a catheter number 8 or number 10 Fr with interrupted chromic gut sutures number 5 - 0 or number 6-0 on Atraumatic needles.

(3) Penile reformation.

(a) The scrotal flaps are made prior to lifting the penis from the scrotum. A catheter is placed in the penile urethra. By dissection, the penis with its established new urethra is lifted off the scrotum.

(b) The flaps are sutured, providing the proper penoscrotal angle.

(c) The scrotal fascia of the flap may be sutured.

(d) A catheter may be placed. The wound is dressed.

3-39. CIRCUMCISION

a. General.

(1) This procedure is the excision of the foreskin (prepuce) of the glans penis. It is done prophylactically in infancy and is commonly performed in the newborn period. For Jewish patients, this may be a religious rite performed by a rabbi. Provision should be made in a hospital to observe the religious needs and preferences of parents in this regard.

(2) Circumcision is done for the relief of phimosis, a condition in which the orifice of the prepuce is too small to permit easy retraction behind the glans. Circumcision may be done to relieve paraphimosis, a condition in which the prepuce cannot be reduced from a retracted position.

b. Patient Preparation. Newborn infants are generally positioned on specially constructed boards that facilitate restraint by immobilizing the limbs and exposing the genitalia. No anesthesia is used for newborn infants. Older patients may be given a general or local anesthetic.

c. Operative Procedure.

(1) If the foreskin is adherent, a probe or hemostat may be used to break up adhesions. The foreskin is grasped with an Allis forceps and stretched taut over the glans. A superficial, circumferential incision is made in the skin at the level of the coronal sulcus at the base of the glans. A straight hemostat may be placed at the medial dorsal aspect and the foreskin cut from the meatus to the sulcus with a straight scissors or scalpel. The foreskin is then completely excised at the level of the sulcus. Bleeding vessels are clamped with mosquito hemostats and tied with fine number 2-0 plain gut ligatures.

(2) The raw edges of the skin incision are approximated along the corona with fine number 4-0 chromic sutures on Atraumatic needles. The wound may be dressed with petrolatum or hemostatic gauze, if desired.

(3) The plastibell method for infants is done in a somewhat different way. A dorsal slit is made, adhesions freed, and the bell placed over the glans inside the foreskin. A suture is tied lightly around the bell, compressing the foreskin into the groove. The free skin is trimmed and the bell handle is broken off.

3-40. URETHRAL MEATOTOMY

a. **General.** This involves incisional enlargement of the external urethral meatus. The procedure is done to relieve stenosis or stricture.

b. **Patient Preparation.** For the male, a supine position is generally used, and the penis is elevated on a small folded sheet. For the female, the lithotomy position is used. Either general or topical anesthesia may be used. Cocaine 5 percent is used for the meatus and 2 percent procaine with bulb syringe is used for instillation into the urethra.

c. **Operative Procedure.** A straight hemostat is applied to the ventral surface of the meatus. An incision is made along the frenulum to enlarge the opening and overcome the stricture. Bleeding vessels are clamped and ligated with fine plain surgical gut sutures. The mucosal layer is sutured up to the skin with fine plain gut sutures. A dressing of petrolatum gauze may be applied.

3-41. EXCISION OF URETHRAL CARUNCLE

a. **General.** This procedure involves the removal of papillary or sessile tumors of the urethra. It is done to rectify an inflammatory prolapse from the lower lip of the female urinary meatus.

b. **Operative Procedure for the Removal of Papillary Growth.** The growth is exposed, clamped at its base with curved hemostats, and excised. A urethral indwelling catheter is inserted into the bladder. The wound is closed.

c. **Operative Procedure for Removal of Sessile Growth.** A circular skin incision is made around the meatus and carried through the submucosal layer. The urethra is freed from the caruncle, the meatus is dissected back to the healthy tissue, and the diseased portion of the urethra is excised. The mucocutaneous junction is approximated with fine chromic gut sutures. An indwelling urethral catheter is introduced and is kept in the bladder for at least 5 days.

3-42. URETHRAL DILATATION AND INTERNAL URETHROTOMY

a. **General.** This procedure involves the gradual dilatation and removal of a urethral stricture to provide for adequate urinary drainage of the kidney.

b. **Operative Procedure for Gradual Dilatation.** The urethra is lubricated and anesthetized. In the male patient, the penis is clamped and the urethra anesthetized. A

filiform bougie is passed through the urethral stricture into the bladder. Sounds or followers of desired type attached to filiform bougies are then passed into the bladder.

c. **Operative Procedure for Internal Urethrotomy.** The filiform bougie is passed into the bladder; the urethrotome is connected and inserted. The Otis urethrotome consists of a curved sound with a groove on its upper side, along which is a triangular knife. Its sides are sharp and its apex blunt. The urethrotome is inserted, and then the blade is released to cut the stricture. Electrosurgical cutting and coagulating electrodes may be used.

3-43. CYSTOSCOPY

a. **General.** This procedure is the visual inspection of the interior of the bladder and examination of adjacent structures by means of an instrument (cystoscope) introduced via the urethra into the bladder. The examination may be done as an end in itself, or may be the first step in a series of examinations or treatments that may be accomplished transurethrally.

b. **Patient Preparation.** The patient is placed in the lithotomy position perineal, preparation is carried out, and the patient is draped with a lithotomy fenestrated sheet and leggings. Surgical jelly is required to lubricate instruments passed into the urethra. A local or general anesthetic may be administered. The surgeon will require a circulator, but probably not a scrub assistant.

c. Operative Procedure.

(1) The surgeon assembles the cystoscope, fitting the obturator into the sheath. The light is tested, and the circulating team member adjusts the current to the proper brightness.

(2) The instrument is lubricated and inserted into the patient's urethra. The obturator is removed and the telescope inserted into the sheath. The surgeon puts his eye to the eyepiece and makes his examination. The bladder is distended with irrigating fluid. The surgeon adjust the flow and volume with the stopcock. Then the obturator or telescope is removed, the irrigating fluid flows out.

(3) Other procedures such as catheterization, biopsy, or stone removal are carried out by exchanging or supplementing the cystoscope lens with the appropriate accessory instrument.

(4) Kidney function studies, cystometry, and X-ray examinations may be performed and various specimens of urine collected. When the examination is concluded, the instrument is removed. A urethral catheter may be inserted as required.

3-44. TRANSURETHRAL SURGERY

a. **General.** By means of a resectoscope passed into the bladder via the urethra, piecemeal resection of the prostate gland and of tumors of the bladder and bladder neck may be carried out, and bleeding vessels and tumors may be fulgurated.

b. **Operative Procedure.** See Figure 3-12.

(1) The resectoscope is assembled. The sheath is fitted with its obturator. The electrode and telescope are attached to the working element. The irrigating system is connected to the sheath. The lamp cord or fiberoptic bundle is fitted to the telescope. The electrode is attached to the electro-surgical unit. The currents are adjusted as the surgeon directs.

(2) The surgeon lubricates the sheath containing the obturator and inserts it into the urethra and bladder. The obturator is removed, and the operating element is introduced through the sheath.

(3) Viewing the anatomy through the telescope, the surgeon begins the electro-dissection, alternately cutting and coagulating. The bladder is permitted to drain--washing out blood tissue and clots--and refill at intervals. The operating element may be removed and evacuating devices such as the Ellik applied, to flush out the bladder.

(4) When the stones are present, they are trapped or crushed with dislodgers or lithotrites, and copious irrigations are done.

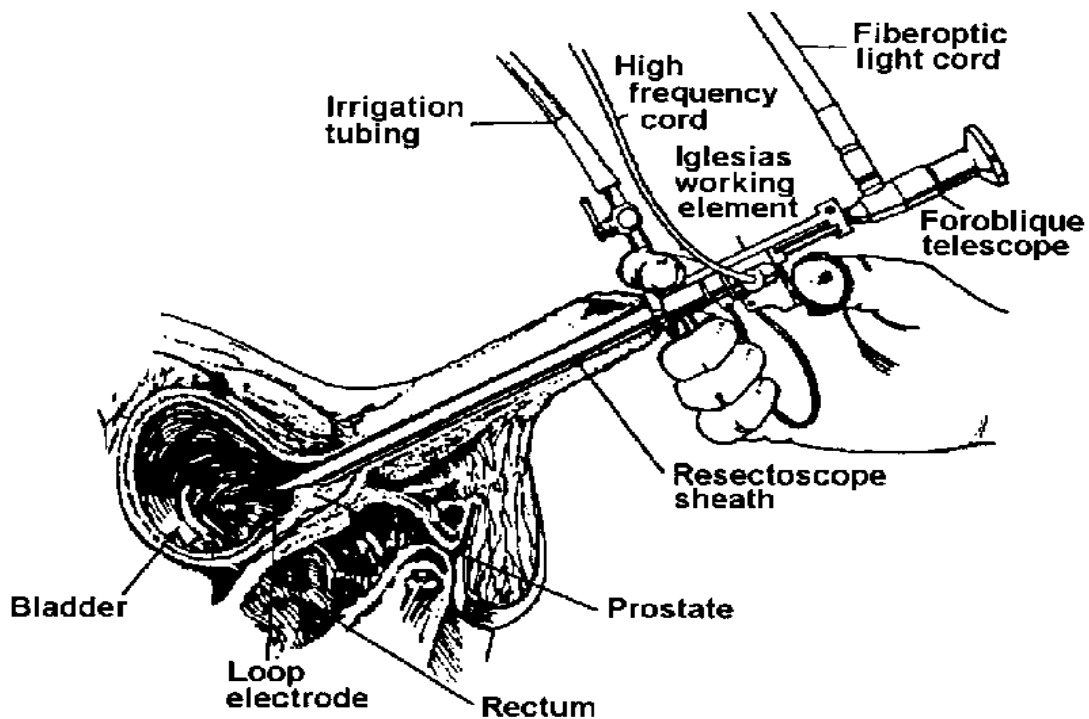


Figure 3-12. Transurethral resection of bladder tumor.

(5) When resection of the lesion is completed and bleeding controlled, the operating instrument is removed. A Foley catheter is introduced. A catheter stylet may be employed. The bag of the catheter is filled, using a 30-ml syringe and adapter. The catheter may be a self-inflating type or have a valve that requires no clamp to retain the fluid in the hemostatic bag. The catheter is flushed for patency, irrigating with an Asepto syringe. When the surgeon is satisfied that the patient's condition is good, the patient is transferred from the operating table.

Continue with Exercises

EXERCISES, LESSON 3

INSTRUCTIONS: The following exercises are to be answered by marking the lettered response that best answers the question or best completes the incomplete statement or by writing the correct word or phrase in the space provided.

After you have completed all the exercises turn to "Solutions to Exercises" at the end of the lesson and check your answers.

1. The urinary bladder is partly in the abdomen when it is:
 - a. Full.
 - b. Empty.
 - c. Healthy.
 - d. Infected.

2. A ureter extends from the _____ to the _____.
 - a. Renal pelvis, bladder.
 - b. Calyces, renal pelvis.
 - c. Bladder, outside.
 - d. Kidney, outside.

3. The renal pelvis is in the shape of a:
 - a. Butterfly.
 - b. Funnel.
 - c. Ball.
 - d. Hand.

4. Adrenalectomy may be done to:
 - a. Remove adrenal tumors.
 - b. Treat hyperfunction of adrenals.
 - c. Discourage cancers elsewhere in the body.
 - d. All of the above.

5. What organ serves as the passageway for urine from the bladder to be eliminated from the body?
 - a. Ureter.
 - b. Urethra.
 - c. Prostate.
 - d. Seminal vesicles.

6. The tubes in which sperm cells are actually formed are in the:
 - a. Spermatic cord.
 - b. Prostate gland.
 - c. Epididymides.
 - d. Testes.

7. Besides adrenalin (epinephrine), the adrenal glands secrete_____ and other hormones.
 - a. Insulin.
 - b. Steroids.
 - c. Thyroxin.
 - d. Testosterone.

8. Kidney stones should always be placed in Formalin solution®.
- True.
 - False.
9. Application of antiseptic in perineal skin preps is different from other areas because many surgeons prefer to apply antiseptic to this area with:
- Inhalation.
 - Cotton balls.
 - Gauze sponges.
 - Spray apparatus.
10. Heminephrectomy is an operation in which a:
- Kidney is removed.
 - Kidney is resected.
 - Donor kidney is placed.
 - Kidney stone is removed.
11. Nephroureterectomy usually requires _____ separate incisions.
- 0.
 - 1.
 - 2.
 - 3.

12. According to this subcourse, the kidneys are ordinarily positioned at approximately the twelfth thoracic vertebra to the _____ lumbar vertebra.
- First.
 - Second.
 - Third.
 - Fourth.
13. Tocar cystostomy involves draining the bladder by:
- Incision.
 - Resection.
 - Blind puncture.
 - Urethral catheter.
14. The Marshall-Marchetti operation is performed on:
- Males.
 - Females.
 - Newborns.
 - Males and females.
15. For vesical-urethral suspension, a _____ incision is used.
- Midline.
 - McBurney.
 - Suprapubic.
 - Midparamedian rectus.

16. An enlarged prostate is always benign.
- a. True.
 - b. False.
17. Suprapubic prostatectomy with cystostomy includes:
- a. Adrenalectomy.
 - b. Ureteral anastomosis.
 - c. Trocar blind puncture.
 - d. Incision of the bladder.
18. What shape excision is made in the neck of the bladder during retropubic prostatectomy?
- a. Semicircle.
 - b. Rectangle.
 - c. Square.
 - d. Wedge.
19. Pads are used under the buttocks for which kind of prostatectomy?
- a. Perineal.
 - b. Retropubic.
 - c. Suprapubic.
 - d. Transurethral.

20. Ligation and partial excision of dilated veins in the scrotum may be done to reduce venous congestion. This procedure is called:
- a. Vasectomy.
 - b. Orchiectomy.
 - c. Hydrocelectomy.
 - d. Varicocelectomy.
21. The operation to bring an undescended testicle into place is called:
- a. Hypospadias repair.
 - b. Varicocelectomy.
 - c. Orchiectomy.
 - d. Orchiopexy.
22. When the urethral meatus is on the upper side of the penis, this is called:
- a. Chordee.
 - b. Epispadias.
 - c. Hypospadias.
 - d. Cryptorchidism.
23. Stenosis of the external urethral meatus requires that the meatus be:
- a. Reduced in size.
 - b. Transposed.
 - c. Cauterized.
 - d. Enlarged.

24. A papillary tumor of the urethra is called a _____:
- a. Urethral caruncle.
 - b. Mitral annuls.
 - c. Carcinoma.
 - d. Empyema.

Special Instructions for Exercises 25 Through 34. Each numbered item in **Column A** can be matched best by one of the letter choices in **Column B**. Write the letter of the **best** answer to the left of the number in **Column A**.

Column A	Column B
_____ 25. Nephrotomy	a. Incision into renal pelvis.
_____ 26. Pyelotomy	b. Removal of small stone(s) from renal pelvis.
_____ 27. Pyelostomy	c. Removal of staghorn calculus.
_____ 28. Pyelolithotomy	d. Opening of a kidney for drainage.
_____ 29. Nephrostomy	e. Opening of the renal pelvis for drainage.
_____ 30. Nephrolithotomy	f. Simple kidney incision.
_____ 31. Cystotomy	g. Bladder is opened to removed stones.
_____ 32. Cystolithotomy	h. Bladder is excised.
_____ 33. Cystostomy	i. Bladder is cut open.
_____ 34. Cystectomy	j. Bladder is opened for continuous drainage.

Special Instructions for Exercise 35. Write the name in the correct column for the male reproductive organs that are found in pairs and those that appear singly.

Testis
Prostate
Ejaculatory duct

Seminal vesicle
Urethra

Seminal duct
Cowper's gland

35.

PAIRS	SINGLY

Check Your Answers on Next Page

SOLUTIONS TO EXERCISES, LESSON 3

1. a (para 3-4a)
2. a (para 3-3)
3. b (para 3-2d)
4. d (para 3-21a)
5. b (para 3-1)
6. d (para 3-7b)
7. b (para 3-8)
8. b (para 3-13b)
9. d (para 3-10a)
10. b (para 3-15a, b)
11. c (para 3-17a)
12. c (para 3-2a)
13. c (para 3-23a)
14. b (para 3-27a)
15. c (para 3-27c(1))
16. b (para 3-28a)
17. d (para 3-28c(4))
18. d (para 3-29b(3))
19. a (para 3-30b)
20. d (para 3-35a)
21. d (para 3-37a)

- 22. b (para 3-38b(3))
- 23. d (para 3-40a)
- 24. a (para 3-41a)
- 25. f (para 3-16a(1))
- 26. a (para 3-16a(2))
- 27. e (para 3-16a(3))
- 28. b (para 3-16a(4))
- 29. d (para 3-16a(5))
- 30. c (para 3-16a(6))
- 31. i (para 3-22b(2))
- 32. g (para 3-22b(2))
- 33. j (para 3-22b(3))
- 34. h (para 3-22b(4))

35. **PAIRS**

Testis
Ejaculatory duct
Seminal Vesicle
Seminal duct

SINGLY

Prostate
Urethra

(para 3-7a)

End of Lesson 3